

## CASE REPORTS

### Endoscopic management of intratracheal ectopic thyroid

KEITH M. PRITCHYK, MD, LESTER D. R. THOMPSON, MD, and SONYA MALEKZADEH, MD, Washington, DC

**A** 19-year-old woman with a long-standing history of asthma presented with increasing shortness of breath on exercise. Over the next 4 months, her symptoms progressively worsened to shortness of breath at rest. A noncontrast computed tomography (CT) scan of the chest revealed a large subglottic soft-tissue mass (Fig 1). On fiberoptic laryngoscopy, a near-obstructing submucosal mass was identified. Bilateral vocal folds were mobile. Routine laboratory tests, including thyroid function tests, were normal, and the patient had a negative pregnancy test. The patient was taken to the operating room, where the airway was secured with an awake tracheotomy. Direct laryngoscopy and bronchoscopy confirmed a smooth, broad-based, submucosal mass arising from the left subglottis and occluding approximately 80% of the airway (Fig 2). On biopsy, the lesion was found to be firm, semicompressible, and highly vascular. Magnetic resonance imaging (MRI) of the neck with gadolinium was obtained, and T2-weighted images demonstrated an intraluminal, uniformly enhancing subglottic lesion measuring 1.3 cm in maximum diameter. The thyroid gland was normal.

The histopathologic examination revealed normal thyroid tissue in the submucosa without evidence of malignancy.

The patient was taken to the operating room for endoscopic resection of the intratracheal ectopic thyroid (ITET) tissue. Suspension laryngoscopy

with the operative microscope and a combination of the neodymium:yttrium-aluminum-garnet (Nd:YAG) and carbon dioxide (CO<sub>2</sub>) lasers was used to perform a gross excision of the mass. Initially, the Nd:YAG was used in the contact mode for precision cutting at the base of the lesion. Although a near-total resection was achieved, this method resulted in excessive hemorrhage of this excessively vascular lesion. Because of the risk of increased depth of penetration at the tracheal wall, the Nd:YAG laser was aborted and the CO<sub>2</sub> laser was used for control of hemostasis. To avoid violating the tracheal wall, clear margins were not achieved. The patient tolerated plugging trials and was decannulated 10 days after surgery. She was started on thyroid suppression therapy to prevent hypertrophy of the remnant intratracheal thyroid tissue. She is alive and well without any sequelae at 2 month after surgery.

#### DISCUSSION

ITET represents 6% to 7% of all primary endotracheal tumors.<sup>1</sup> More than 120 cases of ITET have been reported in the world's literature, affecting women more frequently than men between the ages of 30 and 50.<sup>2</sup> The most common clinical presentation is progressive shortness of breath, often mistaken for asthma.<sup>3</sup>

ITET tissue can originate anywhere between the glottis and the carina. Typically, it presents as a broad-based, smooth, rounded mass protruding from the posterolateral subglottic wall into the tracheal lumen.<sup>3</sup> Multiple nodules, ulceration, and hemorrhage are unusual in true ectopic thyroid and should arouse suspicion of carcinoma.<sup>3</sup> Despite the malignancy potential, ITET represents a curable cause of slowly progressive and sometimes fatal obstruction of the upper respiratory tract.<sup>4</sup>

ITET is symptomatically manifested by progressive dyspnea, cough, and stridor. ITET may declare itself after the normally positioned thyroid has been removed with resultant physiologic hy-

---

From the Department of Otolaryngology – Head and Neck Surgery, Georgetown University Medical Center (Drs Pritchyk and Malekzadeh), and Armed Forces Institute of Pathology (Dr Thompson).

Reprint requests: Keith Pritchyk, MD, Department of Otolaryngology–Head and Neck Surgery, Georgetown University Hospital, 3800 Reservoir Rd, Washington, DC 20007; e-mail, pritchyk@aol.com.

Otolaryngol Head Neck Surg 2004;130:630-2.

0194-5998/\$30.00

Copyright © 2004 by the American Academy of Otolaryngology–Head and Neck Surgery Foundation, Inc.

doi:10.1016/j.otohns.2003.09.032

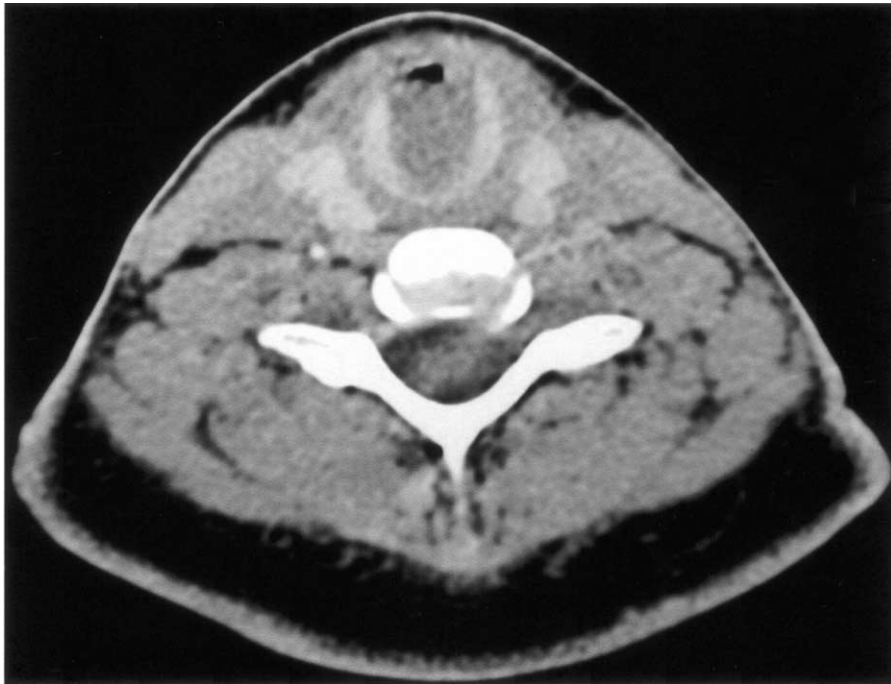


Fig 1. A noncontrast computed tomography scan of the chest revealed a large subglottic soft-tissue mass.

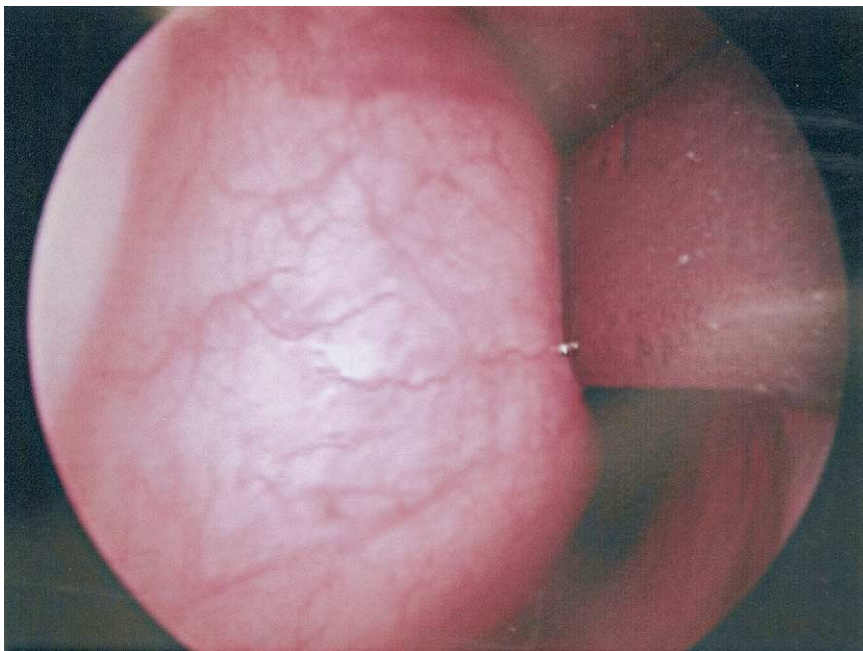


Fig 2. Direct laryngoscopy and bronchoscopy confirmed a smooth, broad-based, submucosal mass arising from the left subglottis and occluding approximately 80% of the airway.

pertrophy of the ectopic tissue.<sup>1</sup> Varying hormone levels associated with menses and pregnancy may aggravate the dyspnea associated with ITET due to alternating hyperplasia and involution.<sup>4</sup>

In patients with signs and symptoms of upper airway obstruction, a CT scan of the neck without contrast is the initial study of choice to identify the site of the lesion. MRI with gadolinium will add

further information regarding the vascularity, density, and heterogeneity of the lesion.

With current laser technology and advanced laryngeal instrumentation, we opted to manage our patient with an endoscopic approach, thereby avoiding the morbidity of an open laryngofissure procedure. A laser endoscopic excision is acceptable provided thyroid malignancy can be excluded. The Nd:YAG and CO<sub>2</sub> lasers, used in combination, provide the best results for precise resection and hemostatic control. Cautious laser dissection along the medial aspect of the tracheal wall to avoid violation of the airway will result in incomplete resection of ectopic thyroid. The residual thyroid tissue must be controlled with thyroid hormone suppression to prevent further growth.

## CONCLUSIONS

ITET is a rare cause of upper airway obstruction. CT scan of the neck without contrast should be performed to evaluate the location of obstruction. MRI scan should be used to assess the extent and vascular nature of the lesion. Endoscopic laser excision is an appropriate treatment option for benign and vascular ITET tissue.

## REFERENCES

1. Fish J, Moore RM. Ectopic thyroid tissue and ectopic thyroid carcinoma: review of the literature and report of a case. *Ann Surg* 1963;157:2.
2. Dossing H, Jorgensen KE, Oster-Jorgensen E, et al. Recurrent pregnancy-related upper airway obstruction caused by intratracheal ectopic thyroid tissue. *Thyroid* 1999;9:955-8.
3. Donegan JO, Wood MD. Intratracheal thyroid—familial occurrence. *Laryngoscope* 1985;95:68-8.
4. Dowling EA, Johnson IM, Collier FCD, et al. Intratracheal goiter. *Ann Surg* 1962;156:258-67.