

Protocol for the Examination of Specimens from Patients with Carcinoma of the Adrenal Gland

Protocol applies to adrenal cortical carcinoma only. Cortical adenomas, pheochromocytoma, neuroblastic tumors, and adrenal tumors of childhood are not included.

Based on AJCC/UICC TNM, 7th edition
Protocol web posting date: October 2009

Procedures

- Biopsy
 - Needle Core
 - Incisional
 - Excisional
- Adrenalectomy

Authors

Jacqueline Wieneke, MD, FCAP*

Department of Endocrine and Otorhinolaryngic Pathology, The Armed Forces Institute of Pathology, Washington, DC

Mahul Amin, MD, FCAP

Department of Pathology and Laboratory Medicine, Cedars-Sinai Medical Center, Los Angeles, California

Sam S. Chang, MD

Department of Urologic Surgery, Vanderbilt-Ingram Cancer Center, Nashville, Tennessee

Clara S. Heffess, MD

Department of Endocrine and Otorhinolaryngic Pathology, The Armed Forces Institute of Pathology, Washington, DC

Ernest E. Lack, MD

Department of Pathology, Washington Hospital Center, Washington, DC

Lester D.R. Thompson, MD, FCAP

Department of Pathology, Southern California Permanente Medical Group, Woodland Hills, California

Lawrence M. Weiss, MD, FCAP

Department of Pathology, City of Hope National Medical Center Duarte, California

Bruce M. Wenig, MD, FCAP†

Department of Pathology and Laboratory Medicine, Beth Israel Medical Center, St. Luke's and Roosevelt Hospitals, New York, New York

For the Members of the Cancer Committee, College of American Pathologists

*denotes primary author. † denotes senior author. All other contributing authors are listed alphabetically.

Previous contributors: Edward Paloyan, MD; Geoffrey Smoron, MD; Ronald A. DeLellis, MD; Ernest E. Lack, MD

© 2009 College of American Pathologists (CAP). All rights reserved.

The College does not permit reproduction of any substantial portion of these protocols without its written authorization. The College hereby authorizes use of these protocols by physicians and other health care providers in reporting on surgical specimens, in teaching, and in carrying out medical research for nonprofit purposes. This authorization does not extend to reproduction or other use of any substantial portion of these protocols for commercial purposes without the written consent of the College.

The CAP also authorizes physicians and other health care practitioners to make modified versions of the Protocols solely for their individual use in reporting on surgical specimens for individual patients, teaching, and carrying out medical research for non-profit purposes.

The CAP further authorizes the following uses by physicians and other health care practitioners, in reporting on surgical specimens for individual patients, in teaching, and in carrying out medical research for non-profit purposes: (1) **Dictation** from the original or modified protocols for the purposes of creating a text-based patient record on paper, or in a word processing document; (2) **Copying** from the original or modified protocols into a text-based patient record on paper, or in a word processing document; (3) The use of a **computerized system** for items (1) and (2), provided that the Protocol data is stored intact as a single text-based document, and is not stored as multiple discrete data fields.

Other than uses (1), (2), and (3) above, the CAP does not authorize any use of the Protocols in electronic medical records systems, pathology informatics systems, cancer registry computer systems, computerized databases, mappings between coding works, or any computerized system without a written license from CAP. Applications for such a license should be addressed to the SNOMED Terminology Solutions division of the CAP.

Any public dissemination of the original or modified Protocols is prohibited without a written license from the CAP.

The College of American Pathologists offers these protocols to assist pathologists in providing clinically useful and relevant information when reporting results of surgical specimen examinations of surgical specimens. The College regards the reporting elements in the "Surgical Pathology Cancer Case Summary (Checklist)" portion of the protocols as essential elements of the pathology report. However, the manner in which these elements are reported is at the discretion of each specific pathologist, taking into account clinician preferences, institutional policies, and individual practice.

The College developed these protocols as an educational tool to assist pathologists in the useful reporting of relevant information. It did not issue the protocols for use in litigation, reimbursement, or other contexts. Nevertheless, the College recognizes that the protocols might be used by hospitals, attorneys, payers, and others. Indeed, effective January 1, 2004, the Commission on Cancer of the American College of Surgeons mandated the use of the checklist elements of the protocols as part of its Cancer Program Standards for Approved Cancer Programs. Therefore, it becomes even more important for pathologists to familiarize themselves with these documents. At the same time, the College cautions that use of the protocols other than for their intended educational purpose may involve additional considerations that are beyond the scope of this document.

The inclusion of a product name or service in a CAP publication should not be construed as an endorsement of such product or service, nor is failure to include the name of a product of service to be construed as disapproval.

Surgical Pathology Cancer Case Summary (Checklist)

Protocol web posting date: October 2009

ADRENAL GLAND: Biopsy (Core Needle, Incisional, Excisional); Resection

Select a single response unless otherwise indicated.

Specimen

Adrenal gland; received:

- Fresh
 In formalin
 Other (specify): _____

Procedure

- Needle biopsy (radiographically guided)
 Adrenalectomy, total
 Adrenalectomy, partial
 Other (specify): _____
 Not specified

Specimen Integrity

- Intact
 Fragmented

Specimen Size

Greatest dimensions: ___ x ___ x ___ cm

*Additional dimensions (if more than one part): ___ x ___ x ___ cm

Specimen Laterality

- Right
 Left
 Not specified
 Other (specify): _____

Tumor Size (Note A)

Greatest dimension: ___ cm

*Additional dimensions: ___ x ___ cm

Cannot be determined (fragmented specimen)

Tumor Gland Weight (Note B)

Specify: ___ g

* Data elements with asterisks are not required. However, these elements may be clinically important but are not yet validated or regularly used in patient management.

***Tumor Description (select all that apply)**

- * Hemorrhagic
- * Necrotic
- * Invasion:
 - * Capsule
 - * Vessels
 - * Extra-adrenal (specify): _____
- * Other (specify): _____

Histologic Type (Notes C through E)

Adrenal cortical carcinoma

***Microscopic Tumor Extension**

*Specify: _____

Margins

- Margins uninvolved by tumor
- Margin(s) involved by tumor
 - Distance from closest margin: ____ mm or ____ cm
 - Specify margin(s) if possible: _____
- Cannot be determined
- Not applicable

***Treatment Effect (applicable to carcinomas treated with neoadjuvant therapy)**

- * Not identified
- * Present (specify): _____
- * Indeterminate

Lymph-Vascular Invasion (select all that apply) (Note F)

- Not identified
- Present
 - Large vessel (venous)
 - Small vessel (capillary lymphatic)
- Indeterminate

***Perineural Invasion**

- * Not identified
- * Present
- * Indeterminate

***Lymph Nodes, Extranodal Extension**

- * Not identified
- * Present
- * Indeterminate

* Data elements with asterisks are not required. However, these elements may be clinically important but are not yet validated or regularly used in patient management.

Pathologic Staging (pTNM) (Note G)

TNM Descriptors (required only if applicable) (select all that apply)

- m (multiple primary tumors)
 r (recurrent)
 y (post- treatment)

Primary Tumor (pT)

- pTX: Cannot be determined
 pT0: No evidence of primary tumor
 pT1: Tumor 5 cm or less in greatest dimension, no extra-adrenal invasion
 pT2: Tumor greater than 5 cm, no extra-adrenal invasion
 pT3: Tumor of any size with local invasion, but not invading adjacent organs[#]
 pT4: Tumor of any size with invasion of adjacent organs[#]

[#] *Adjacent organs include kidney, diaphragm, great vessels, pancreas, and liver.*

Note: There is no category of carcinoma in situ (pTis) relative to carcinomas of the adrenal gland.

Regional Lymph Nodes (pN) (Note H)

- pNX: Cannot be assessed
 pN0: No regional lymph node metastasis
 pN1: Regional lymph node metastasis

Specify: Number examined: ____
 Number involved: ____

Distant Metastasis (pM) (Note I)

- Not applicable
 pM1: Distant metastasis
 *Specify site(s), if known: _____

***Additional Pathologic Findings (select all that apply)**

- * None identified
 * Tumor necrosis
 * Degenerative changes
 * Calcifications
 * Hemorrhage
 * Cystic change
 * Other (specify): _____

*** Non-Pathology Findings (select all that apply) (Notes J and K)**

- * Urinary 17-ketosteroids increased (10 mg/g creatinine/24 hours)
 * Hormone production
 * Cushing syndrome
 * Conn syndrome
 * Virilization/feminization
 * Weight loss
 * Other (specify): _____

* Data elements with asterisks are not required. However, these elements may be clinically important but are not yet validated or regularly used in patient management.

***Ancillary Studies (Note L)**

*Specify type(s): _____

*Specify result(s): _____

***Clinical History (select all that apply)**

* ___ Neoadjuvant therapy

* ___ Yes (specify type): _____

* ___ No

* ___ Indeterminate

* ___ Other (specify): _____

***Comment(s)**

* Data elements with asterisks are not required. However, these elements may be clinically important but are not yet validated or regularly used in patient management.

Explanatory Notes

A. Primary Site and Laparoscopic Surgery

The adrenal glands sit in a supra renal location (retroperitoneal) surrounded by connective tissue and a layer of adipose tissue. The adrenal glands are intimately associated with the kidneys and are enclosed within the renal fascia (Gerota's). Each gland has an outer cortex, which is lipid rich and on gross examination appears bright yellow, surrounding an inner "gray-white" medullary compartment composed of chromaffin cells. There is a rich vascular supply derived from the aorta, inferior phrenic arteries, and renal arteries. Veins emerge from the hilus of the glands. The shorter right central vein opens into the inferior vena cava and the left central vein opens into the renal vein. A single adrenal vein is present for each gland. The regional lymph nodes include the aortic lymph nodes (para-aortic, peri-aortic) and retroperitoneal lymph nodes.

An entire adrenal tumor may be removed laparoscopically, but with this technique, the gland may become fragmented. This anatomic information, including maximal diameter of the resected tumor, should be provided by the surgeon. A recent study¹ demonstrates a tumor size greater than 6.5 cm is likely to be malignant.

B. Weight

Accurate weights of adrenal cortical neoplasms are important.² Although tumor mass cannot be used as the sole criterion for malignancy, adrenal cortical neoplasms weighing less than 50 g are almost always benign, whereas the weight of malignant tumors is usually greater than 100 g. Weight is a reflection of gland weight rather than tumor weight because, in actuality, following surgically excision, the tumor is not dissected from the gland proper and weighed separately.

C. Histologic Type

The following histologic classification of adrenal tumors has been modified from Page et al³ and from the World Health Organization (WHO) classification of tumors of the adrenal gland.⁴ This list may not be complete. This protocol applies only to adrenal cortical carcinoma and does not apply to other tumor types.

Histologic Classification of Adrenal Tumors

Cortical Tumors

- Adenoma
- Oncocytic adrenocortical neoplasm
- Carcinoma[#]

Medullary Tumors

- Pheochromocytoma (benign and malignant)
- Neuroblastoma
- Ganglioneuroblastoma
- Ganglioneuroma

Composite Tumors

- Composite corticomedullary tumor
- Composite pheochromocytoma (Composite paraganglioma)
 - Pheochromocytoma-ganglioneuroblastoma
 - Pheochromocytoma-ganglioneuroma

Extra-Adrenal Paragangliomas

Other Adrenal Tumors

- Adenomatoid tumor
- Hematolymphoid malignancies
- Sex cord-stromal tumor
- Soft tissue tumors and Tumor-like lesions
 - Myelolipoma
 - Teratoma
 - Schwannoma
 - Angiosarcoma

Miscellaneous, including adrenal pseudotumor

Covered in protocol.

D. Histologic Grade

Adrenal cortical carcinomas are not usually graded on histologic grounds. Severe nuclear atypia, high mitotic count, vascular invasion, tumor necrosis, and other microscopic features may, in combination, support a diagnosis of adrenal cortical carcinoma and should be recorded. When several malignant features are present together (eg, highly atypical nuclei, trabecular growth, necrosis, and many mitoses), the risk of distant metastases is increased.^{2,5-7} In some studies, specific combinations of features, such as mitotic rates of >5 per 50 high-power fields (HPF) along with atypical mitosis and venous invasion, have been found to correlate with metastasis or recurrence of adrenal cortical carcinomas.^{1,6} Other studies have shown that mitotic rates greater than 20 per 50 HPF are associated with decreased survival, suggesting that a high mitotic index may be an important adverse prognostic factor.⁷

The criteria used in adults to separate benign from malignant cortical tumors are not entirely applicable to adrenocortical tumors in pediatric age groups. Further, pediatric adrenocortical neoplasms showing histologic features worrisome for malignancy in adults (eg, capsular invasion, vascular invasion, increased mitotic activity, atypical mitoses, necrosis) may not be predictive of biologic behavior; such a pediatric adrenocortical neoplasm exhibiting such histologic features may have a clinically benign course. A number of classification schemes attempting to separate benign from malignant pediatric adrenocortical tumors have been proposed. One of these studies is based on the presence (carcinoma) or absence (adenoma) of 4 histologic features (modified Weiss system) including high nuclear grade, necrosis, mitotic rate greater than 5 per 50 HPF, and atypical mitoses⁸; another study found that tumor weight was the only reliable predictor of behavior, with tumors weighing over 500 g being malignant⁹; and another study correlated tumor volume of greater than 200 cm³ and weight greater than 80 g associated with an adverse outcome.¹⁰ Subsequent to these studies, another study proposed classifying pediatric adrenocortical neoplasms based on a series of 9 criteria including tumor weight greater than 400 g, tumor size greater than 1.5 cm, extension into perirenal soft tissues and/or adjacent organs, invasion into the vena cava, venous invasion, capsular invasion, presence of tumor necrosis, mitotic rate greater than 15 per 20 HPF, and the presence of atypical mitoses¹¹; based on this study, the presence of up to 2 of these criteria was associated with a benign outcome, 3 criteria were considered indeterminate for malignancy, and 4 or more criteria were associated with malignant behavior.

Although this protocol does not cover medullary tumors, it should be noted that pheochromocytoma is usually diagnosed preoperatively by clinical and laboratory

means. Metastatic disease is considered the standard proof of malignancy, but recently a constellation of histologic features that can be used to predict malignant has been proposed.^{12,13}

E. Adrenal Incidentalomas

With the technical advancement and availability of radiographic imaging, many asymptomatic adrenal neoplasms are coming to clinical attention at much smaller limits. Such asymptomatic neoplasms are referred to as “adrenal incidentalomas.” Adrenal incidentalomas can present clinical dilemmas to the treating physician. A consensus statement on how to manage adrenal incidentalomas was proposed in 2002.^{14,15} Follow-up and treatment decisions are based on a combination of clinical/laboratory parameters and tumor size (<4 cm, 4-6 cm, >6 cm).

F. Lymph-Vascular Invasion

According to the Weiss classification,⁶ distinguishing between large vessel (venous) and small vessel (capillary/lymphatic) invasion may have an impact on prognosis, with large caliber vascular space invasion portending a worse prognosis.

G. Staging

The staging system proposed by MacFarlane¹⁶ and modified by Sullivan et al¹⁷ and Henley et al¹⁸ is most commonly used for adrenal cortical carcinomas. The American Joint Committee on Cancer (AJCC) and the International Union Against Cancer (UICC) have accepted this initial TNM staging system for adrenal cortical carcinoma to be published in their 7th editions.¹⁹

Stage	Extent	Size
Stage I	Confined to gland	5 cm or less
Stage II	Confined to gland	Greater than 5 cm
Stage III	Extends out of gland without involving adjacent organs	Any
Stage IV	Distant metastasis or involvement of adjacent organs	Any

*Tumors of the Adrenal Gland and Extra-Adrenal Paraganglia*²⁰ proposes the following staging system:

Primary Tumor (pT) (Figures 1 through 4)

pTX	Primary tumor cannot be assessed
pT0	No evidence of primary tumor
pT1	Tumor 5 cm or less in greatest dimension, no extra-adrenal invasion
pT2	Tumor greater than 5 cm, no extra-adrenal invasion
pT3	Tumor of any size with local invasion, but not invading adjacent organs [#]
pT4	Tumor of any size with invasion of adjacent organs [#]

[#] Note: Adjacent organs include kidney, diaphragm, great vessels, pancreas, and liver.

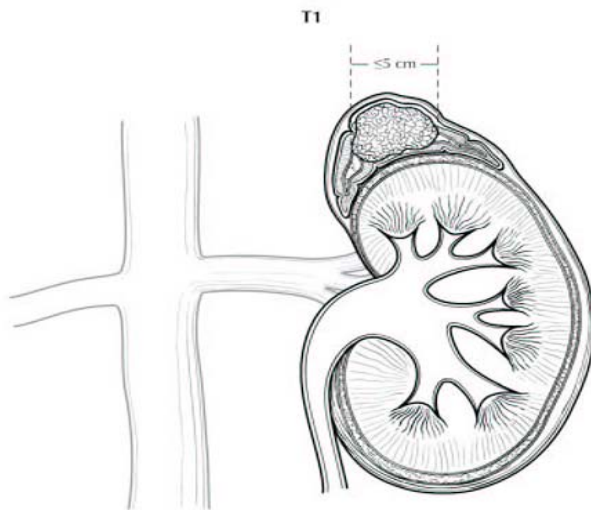


Figure 1. T1: Tumor 5 cm or less in greatest dimension, no extra-adrenal invasion. Used with the permission of the American Joint Committee on Cancer (AJCC), Chicago, Illinois. The original source for this material is the *AJCC Cancer Staging Manual*, 7th ed (2009) published by Springer Science and Business Media LLC, www.springerlink.com.

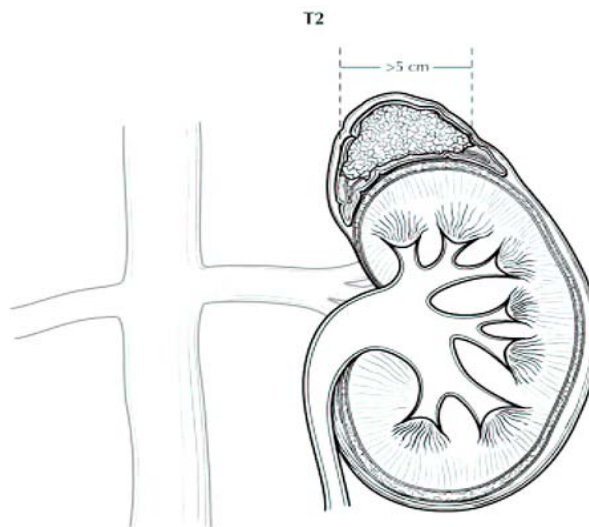


Figure 2. T2: Tumor greater than 5 cm, no extra-adrenal invasion. Used with the permission of the American Joint Committee on Cancer (AJCC), Chicago, Illinois. The original source for this material is the *AJCC Cancer Staging Manual*, 7th ed (2009) published by Springer Science and Business Media LLC, www.springerlink.com.

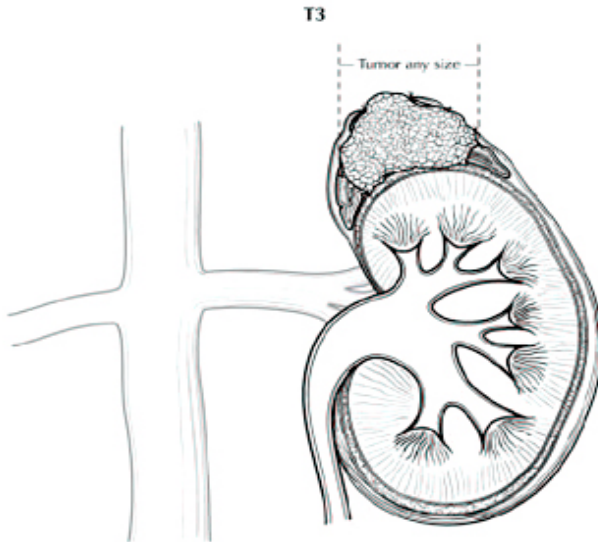


Figure 3. T3: Tumor of any size with local invasion, but not invading adjacent organs. Used with the permission of the American Joint Committee on Cancer (AJCC), Chicago, Illinois. The original source for this material is the *AJCC Cancer Staging Manual*, 7th ed (2009) published by Springer Science and Business Media LLC, www.springerlink.com.

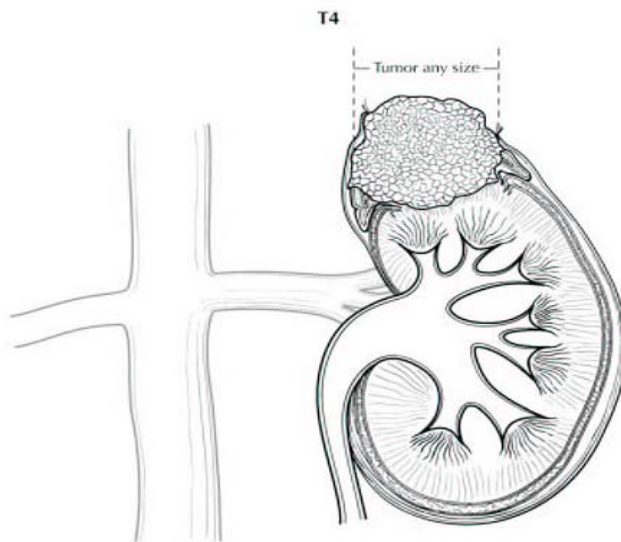


Figure 4. T4: Tumor of any size with invasion of adjacent organs. Used with the permission of the American Joint Committee on Cancer (AJCC), Chicago, Illinois. The original source for this material is the *AJCC Cancer Staging Manual*, 7th ed (2009) published by Springer Science and Business Media LLC, www.springerlink.com.

Regional Lymph Nodes (pN)

- pN0 Negative regional nodes
- pN1 Positive regional nodes

Distant Metastasis (pM)

pM0 No distant metastasis

pM1 Distant metastasis

Stage Definitions

Stage I	T1	N0	M0
Stage II	T2	N0	M0
Stage III	T1	N1	M0
	T2	N1	M0
	T3	N0	M0
Stage IV	T3	N1	M0
	T4	N0	M0
	Any T	Any N	M1

H. Regional Lymph Nodes

Regional lymph nodes include aortic (para-aortic and peri-aortic) and retroperitoneal (peri-nephric and peri-adrenal).

I. Metastatic Sites

Common metastatic sites include liver, lung, and retroperitoneum. Metastases to brain and skin are uncommon although cutaneous involvement of the scalp can simulate angiosarcoma.²⁰

J. Relevant History

Endocrine manifestations, such as hypertension, change in body habitus, feminization, or virilism, are important, as is the knowledge of whether the patient suffers from an adrenal-related disease or syndrome (eg, Cushing disease, Conn syndrome). Also of import are family history, previous surgery for adrenal tumors (both benign and malignant) or other endocrine organs, other tumors that may metastasize to the adrenal gland, and endocrine or other therapies. In addition, while the majority of adrenal cortical carcinomas occur sporadically, occasionally adrenal cortical carcinoma may be associated with hereditary cancer syndromes.^{4,20} Such hereditary cancer syndromes include Li-Fraumeni syndrome or SBLA (sarcoma; breast and brain tumors; leukemia, laryngeal carcinoma and lung cancer; and adrenal cortical carcinoma) syndrome²⁰ and Beckwith-Weidmann syndrome.⁴ Hyperplastic adrenal tissue may re-grow if previously excised incompletely.

K. Endocrine Status

Laboratory findings are important in the evaluation of an adrenal mass. Tumors that are functional, ie, secrete cortisol, aldosterone, or sex hormones, tend to be discovered at an earlier stage than non-functional tumors. Non-functional tumors come to attention due to mass effect and are usually larger.

L. Ancillary Studies

Special procedures may include frozen sections, cytologic imprints, immunohistochemical stains, histochemical stains, electron microscopy, flow cytometry, molecular studies, and cytogenetic studies. If such studies are performed in another laboratory, either extra-institutional or intra-institutional, the laboratory should be identified.

References

1. Aubert S, Wacrenier A, Leroy X, et al. Weiss system revisited: a clinicopathologic and immunohistochemical study of 49 adrenocortical tumors. *Am J Surg Pathol*. 2002;26:1612-1619.
2. Medeiros LJ, Weiss LM. New developments in the pathologic diagnosis of adrenal cortical neoplasms: a review. *Am J Clin Pathol*. 1992;97:73-83.
3. Page DL, DeLellis RA, Hough AJ Jr. *Tumors of the Adrenal. Atlas of Tumor Pathology*. 2nd Series, Fascicle 23. Washington, DC: Armed Forces Institute of Pathology; 1986.
4. DeLellis RA, Lloyd RV, Heitz PU, Eng C, eds. *World Health Organization Classification of Tumours: Pathology and Genetics of Tumours of Endocrine Organs*. Lyon, France: IARC Press; 2004: 136.
5. Hough AJ, Hollifield JW, Page DL, Hartmann WH. Prognostic factors in adrenocortical tumors: a mathematical analysis of clinical and morphologic data. *Am J Clin Pathol*. 1979;72:390-399.
6. Weiss LM. Comparative histologic study of 43 metastasizing and non-metastasizing adrenocortical tumors. *Am J Surg Pathol*. 1984;8:163-169.
7. Weiss LM, Medeiros LJ, Vickery AL. Pathologic features of prognostic significance in adrenal cortical carcinoma. *Am J Surg Pathol*. 1989;13:202-206.
8. Bugg MF, Ribeiro RC, Roberson PK, et al. Correlation of pathologic features with clinical outcome in pediatric adrenocortical neoplasia: a study of a Brazilian group for treatment of childhood adrenocortical tumors. *Am J Clin Pathol*. 1994;101:625-629.
9. Cagle PT, Hough AJ, Pysher TJ, et al. Comparison of adrenal cortical tumors in children and adults. *Cancer*. 1986;57:2235-2237.
10. Ribeiro RC, Sandrini Neto RS, Schell MJ, Lacerda L, Sambaio GA, Cat I. Adrenocortical carcinoma in children: a study of 40 cases. *J Clin Oncol*. 1990;8:67-74.
11. Wieneke JA, Thompson LD, Heffess CS. Adrenal cortical neoplasms in the pediatric population: a clinicopathologic and immunophenotypic analysis of 83 cases. *Am J Surg Pathol*. 2003;27:867-881.
12. Gao B, Meng F, Bian W, et al. Development and validation of pheochromocytoma of the adrenal gland scaled score for predicting malignant pheochromocytomas. *Urology*. 2006;68:282-286.
13. Thompson LDR. Pheochromocytoma of the adrenal gland scaled score (PASS) to separate benign from malignant neoplasms: a clinicopathologic and immunophenotypic study of 100 cases. *Am J Surg Pathol*. 2002;26:551-566.
14. Grumbach MM, Biller BMK, Braunstein GD, et al. Management of the clinically inapparent adrenal mass ("incidentaloma"). *Ann Intern Med*. 2003;138:424-429.
15. NIH state-of-the-science statement on management of the clinically inapparent adrenal mass ("incidentaloma"). *NIH Consens State Sci Statements*. 2002;19:1-25.
16. MacFarlane DA. Cancer of the adrenal cortex: the natural history, prognosis, and treatment in a study of fifty-five cases. *Ann R Coll Surg Engl*. 1958;23:155-186.
17. Sullivan M, Boileau M, Hodges CV. Adrenal cortical carcinoma. *J Urol*. 1978;120:660-665.
18. Henley DJ, van Heerden JA, Grant CS, Carney JA, Carpenter PC. Adrenal cortical carcinoma: a continuing challenge. *Surgery*. 1983;94:926-931.
19. Edge SB, Byrd DR, Carducci MA, Compton CC, eds. *AJCC Cancer Staging Manual*. 7th ed. New York, NY: Springer; 2009.

20. Lack EE. *Tumors of the Adrenal Gland and Extra-Adrenal Paraganglia*. AFIP Fascicle No. 8. Fourth Series. Washington DC: American Registry of Pathology; 2007.