

## Laryngeal granular cell tumor

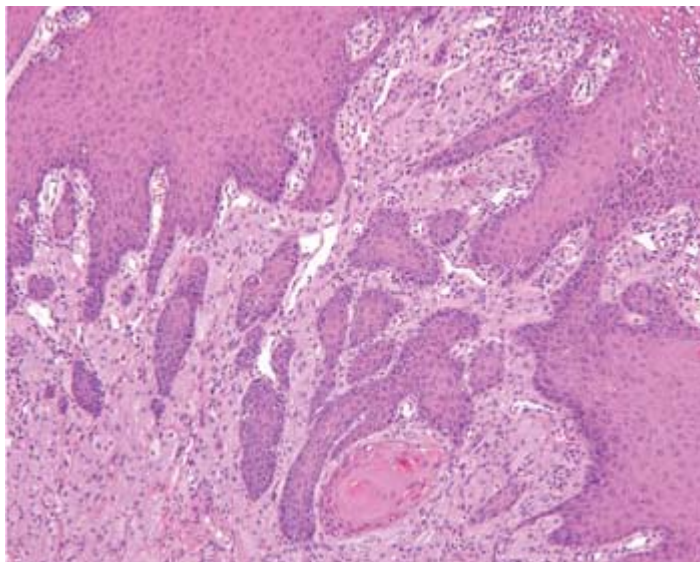
by Lester D.R. Thompson, MD

Granular cell tumors, also called Abrikossoff tumors, are benign, slowly growing neoplasms, presumably of Schwann cell origin. They may occur anywhere in the body, although 50% occur in the head and neck. The most common site is the tongue; the larynx is involved in approximately 10% of all cases. Granular cell tumors typically develop in the fourth and fifth decades of life; they are quite rare in children. Blacks are affected more commonly than other races. A slight female preponderance has been reported. As many as 10% of patients experience multifocal synchronous or metachronous tumors.

Clinically, patients with laryngeal granular cell tumors present with hoarseness, dysphagia, cough and, less frequently, stridor. Most tumors are smaller than 2 cm; larger tumors can cause difficulty breathing. The vast majority of tumors arise from the posterior aspect of the true vocal folds; approximately half of these extend into the subglottis. These tumors are covered with an intact squamous mucosa, and they are smooth, polypoid, firm, homogeneous, and well circumscribed with a gray-yellow cut appearance.

Immediately overlying the mass, the epithelium demonstrates pseudoepitheliomatous hyperplasia in most cases (figure 1). Sometimes the hyperplasia is so florid that it mimics squamous cell carcinoma. The tumor cells are arranged in sheets and clusters, and they are often associated with nerves, which gives them an "infiltrative" appearance. The polygonal to elongated cells are large, and they have indistinct cell borders and a syncytial appearance. The cytoplasm is coarsely granular with a prominent eosinophilia. The nuclei are small and hyperchromatic to vesicular, and they may be centrally or eccentrically located. Mitotic figures, necrosis, and pleomorphism are generally absent. The cytoplasmic granularity can be highlighted by a diastase-resistant, periodic acid-Schiff stain that highlights the lysosomes. The tumor cells are separated by a relatively dense fibrovascular stroma (figure 2, A). They react strongly with immunohistochemical stains against S-100 protein (figure 2, B), vimentin, CD68 (which highlights intracytoplasmic phagolysosomes), neuron-specific enolase, and myelin basic proteins.

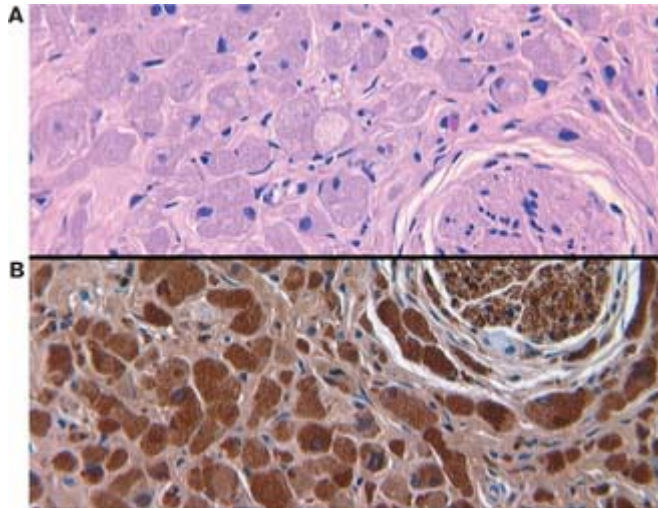
*Florid pseudoepitheliomatous hyperplasia overlies the syncytial arrangement of indistinct, granular, eosinophilic tumor cells*



---

**A:** Fibrous bands separate the large, polygonal tumor cells with abundant eosinophilic, vacuolated, and granular cytoplasm.

**B:** S-100 protein stains both the nucleus and cytoplasm of the tumor cells. Note the entrapped nerve, which serves as a positive internal control for the immunohistochemistry stain and supports the Schwann-cell derivation of the tumor



Because of the distinct microscopic appearance of granular cell tumors, the differential diagnosis is limited. Malignant granular cell tumors are rare in the larynx. Extensive pseudoepitheliomatous hyperplasia can be misinterpreted as an invasive squamous cell carcinoma, even though there is a lack of atypia but increased mitotic figures. Complete local excision will help prevent recurrence while still preserving normal function. Radiotherapy is not used, but long-term follow-up is encouraged.

From the Department of Pathology, Woodland Hills Medical Center, Southern California Permanente Medical Group, Woodland Hills, Calif.

### Suggested reading

1. Arevalo C, Maly B, Eliashar R, Gross M. Laryngeal granular cell tumor. *J Voice* 2008; 22 (3): 339-42.
2. Kamal SA, Othman EO. Granular cell tumour of the larynx. *J Laryngol Otol* 1998; 112 (1): 83-5.