

Osteomyelitis

Francis H. Gannon, MD;
Lester D.R. Thompson, MD

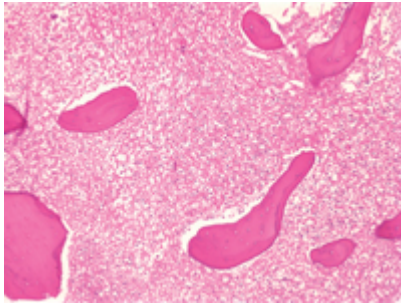


Figure 1. An intermediate-power view of acute osteomyelitis shows marrow edema, bony spicules, necrosis, and acute inflammatory cells.

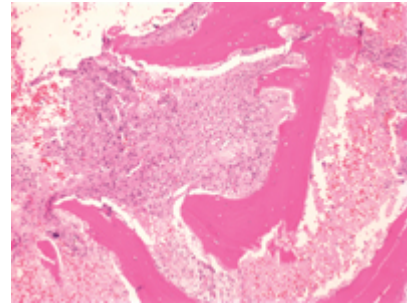


Figure 2. An intermediate-power view of chronic osteomyelitis demonstrates marrow fibrosis with scattered mononuclear cells and fragments of bone.

The proper treatment and clinical management of osteomyelitis (bone infection) depend on a successful correlation of its clinical features with radiologic and pathologic findings. Diagnostic difficulties may arise, and the final arbiter is intraoperative culture. The importance of intraoperative culture obtained in a "sterile" environment cannot be overemphasized.

The three general categories of osteomyelitis are *acute*, *chronic*, and *tuberculous* (the latter is not seen in head and neck locations). Most patients with acute osteomyelitis in the head and neck present with mandibular disease. Osteomyelitis is being seen with increasing frequency in patients with chronic diseases such as diabetes and peripheral vascular disease and in patients with poor dental hygiene; it is uncommon in healthy adults. Because adult patients often present with pain and without an associated fever, a high index of suspicion and the appropriate cultures are required to establish the correct diagnosis and appropriate treatment. The histologic features include marrow edema and delicate fibrosis with acute inflammatory cells and bone resorption (figure 1).

Chronic osteomyelitis is often the result of incomplete treatment of acute osteomyelitis. Approximately 15 to 30% of patients with acute osteomyelitis will develop chronic osteomyelitis. Signs and symptoms of the chronic form are usually less prominent and may fluctuate in severity; they include swelling, pain, sinus formation, sequestration and, in the case of bone loss, pathologic fractures. The histologic features are marrow fibrosis with scattered mononuclear cells (figure 2). Long-standing chronic osteomyelitis is associated with squamous cell carcinoma in approximately 1% of patients.

The treatment of acute osteomyelitis involves an armamentarium of antibiotic agents in addition to debridement and removal of dead bone. Chronic osteomyelitis is more difficult to manage unless all necrotic bone and organisms are removed. Occasionally, resection of large parts of the mandible is necessary to achieve this goal.

Suggested reading

Lazzarini L, Mader JT, Calhoun JH. Osteomyelitis in long bones. *J Bone Joint Surg Am* 2004;86-A:2305-18.
Lew DP, Waldvogel FA. Osteomyelitis. *Lancet* 2004;364:369-79.