

Skin keloid

Lester D.R. Thompson, MD

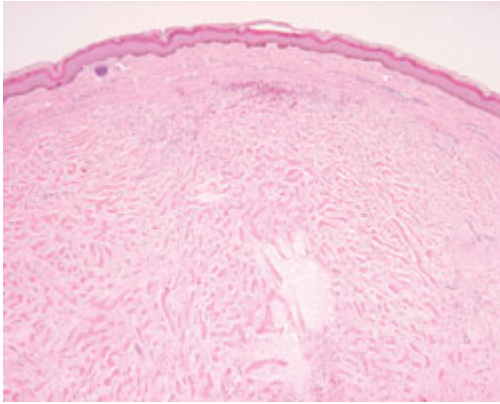
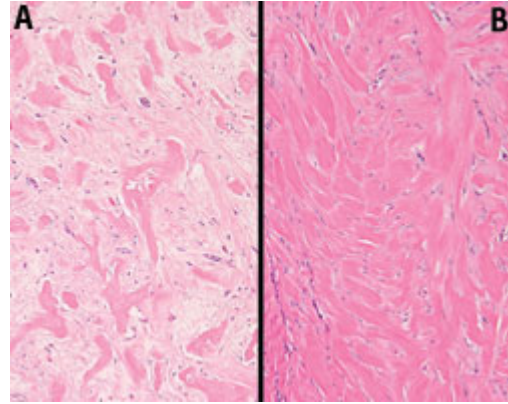


Figure 1. An intact epidermis is separated from the heavy deposition of collagen. The collagen is separated by small bundles of sparsely cellular fibroblastic tissue and chronic inflammatory cells.



*Figure 2. High-power view shows nodules of highly compacted hyalinized collagen deposits. **A:** A few fibroblasts are identified between the collagen bundles. **B:** Cellularity is limited.*

A keloid is a form of excessive scar formation that occurs in response to tissue injury. Keloids arise as a result of abnormal wound healing where there is a disruption of the balance between collagen formation and degradation with a shift toward excess synthesis. Even with injuries that are seemingly minor, the resultant scar formation is disproportionately excessive. The etiology is unknown.

The true incidence and prevalence of keloids are unknown, although we do know that they affect the sexes equally, they are more common in darker-skinned patients, and they are uncommon in the very young and the elderly. In the head and neck, the earlobe is the most common site of involvement.

Macroscopically, keloids are large, prominent scars that extend beyond the margins of the original injury—unlike hypertrophic scars, which are confined to the original wound margins. Outcomes are different, as well; keloids tend to grow and recur, while hypertrophic scars often regress with time.

Histologically, keloids are characterized by excessive collagen and extracellular matrix deposition. Although the epidermis and papillary dermis are generally unaffected, deep in the dermis are thick, tightly packed collagen fibers randomly oriented in irregular sheets (figure 1). The collagen is brightly eosinophilic (figure 2). Generally, an inflammatory response is sparse.

Many treatments have been undertaken, including surgery, laser ablation, steroid injection, radiation, interferon, cryotherapy, pressure therapy, and retinoic acid among many others, but recurrences remain common. Combination therapies seem to yield the best result.

Acknowledgment

The author would like to thank Parul Goyal, MD, for his contribution to this Clinic.

Suggested reading

Haverstock BD. Hypertrophic scars and keloids. *Clin Podiatr Med Surg* 2001;18:147-59.

Urioste SS, Arndt KA, Dover JS. Keloids and hypertrophic scars: Review and treatment strategies. *Semin Cutan Med Surg* 1999;18:159-71.