

Larynx amyloidosis

Lee M. Akst, MD

Lester D.R. Thompson, MD

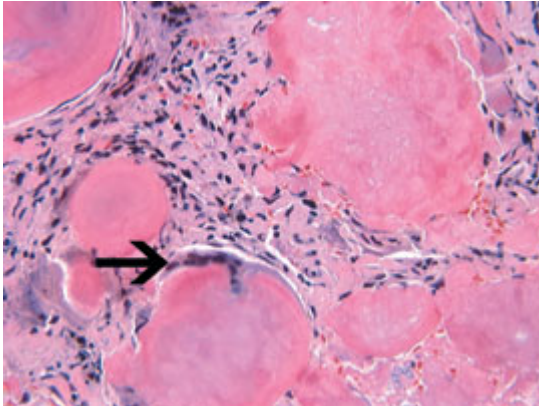


Figure 1. Intermediate-power magnification shows aggregates of acellular, amorphous, eosinophilic extracellular matrix material. A foreign-body-type giant cell with multiple nuclei (arrow) is noted (H&E).

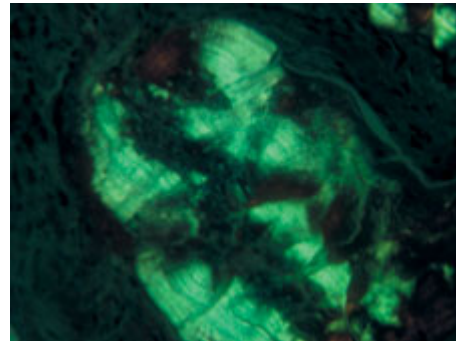


Figure 2. Bright-green birefringence is identified in this polarized micrograph stained with Congo red.

Amyloidosis is a benign accumulation of extracellular, insoluble, fibrillar protein. In general, the deposition of amyloid may be either localized or systemic and either primary or secondary. Laryngeal amyloidosis is rare, accounting for less than 1% of all benign laryngeal tumors. When it does occur, it is commonly localized and primary. Multifocal disease is present in up to 15% of patients. The disease typically manifests as hoarseness or vocal changes in the fifth to sixth decades, and it affects men and women equally.

The ventricles and false vocal folds are affected most frequently, and they exhibit smooth, submucosal nodular to diffuse deposits beneath an intact surface epithelium. Microscopically, there is a subepithelial, extracellular, acellular, amorphous, eosinophilic matrix deposition that is often accentuated around minor seromucus glands and vessels (figure 1). A sparse inflammatory infiltrate predominantly made up of lymphocytes and plasma cells is common, particularly at the leading edge of the amyloid. Foreign-body-type giant cells are also noted. Apple-green birefringence under polarization after staining with Congo red is diagnostic (figure 2). Immunoreactivity with amyloid P and light chains (k and l) is more variable. Electron microscopy reveals the characteristic interlacing meshwork of nonbranching fibrils as the protein arranges itself into β -pleated sheets.

The differential diagnosis includes vocal fold polyps and liginous conjunctivitis, and it is important to note that amyloid may occur in association with multiple myeloma, small cell carcinoma, and medullary thyroid carcinoma. Immunohistochemistry can usually clarify this differential. Laryngeal amyloidosis is a slowly progressive disease, and conservative endoscopic removal of amyloid deposits yields a good result, although recurrent or persistent disease is common. Since laryngeal amyloidosis may be associated with multifocal or systemic disease, appropriate clinical, radiographic, and laboratory investigation—including serum and protein electrophoresis, chest radiographs, and possibly gastrointestinal biopsy—is recommended to exclude systemic disease.

Suggested reading

Lewis JE, Olsen KD, Kurtin PJ, Kyle RA. Laryngeal amyloidosis: A clinicopathologic and immunohistochemical review. *Otolaryngol Head Neck Surg* 1992; 106:372-7.

Thompson LD, Derringer GA, Wenig BM. Amyloidosis of the larynx: A clinicopathologic study of 11 cases. *Mod Pathol* 2000; 13:528-35.