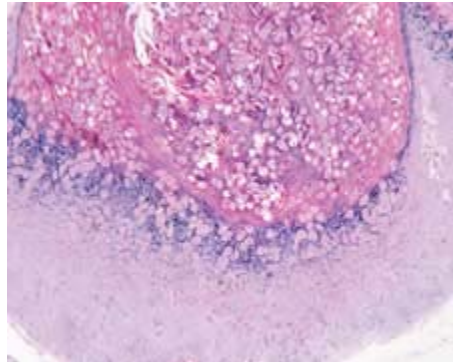
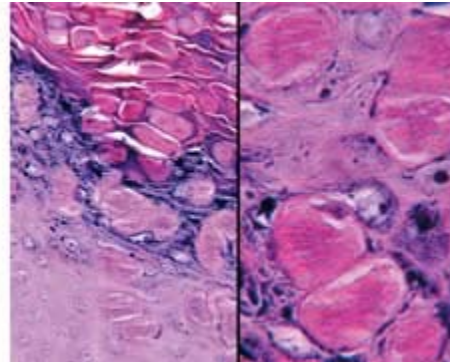


## Molluscum contagiosum

Brenda L. Nelson, DDS  
Lester D.R. Thompson, MD



*Figure 1. Low-power magnification of a skin lesion shows a large number of cell layers and the center crater filled with keratinocytes affected by the poxvirus.*



*Figure 2. Two high-power images demonstrate the viral inclusions in the nuclei of the keratinocytes, usually accentuated above the granular layer (left). The inclusion has an eosinophilic and ground-glass appearance as it expands and destroys the keratinocyte nucleus.*

Molluscum contagiosum is a virus-induced epithelial hyperplasia produced by a DNA poxvirus. This common disease can be found on the skin and mucosal surfaces. It is acquired by direct contact with an infected individual or, less commonly, by contact with a fomite (e.g., clothing, towels, and toys); autoinoculation is common. Molluscum contagiosum is usually seen in children and young adults; immunocompromised persons are especially vulnerable to infection. Lesions predominantly arise on the skin of the face, neck, eyelids, trunk, and genitalia, as well as on the mucous membranes of these areas (as applicable). The incubation period averages between 2 and 7 weeks, although it can be much longer.

In most cases, the clinical appearance of molluscum contagiosum is diagnostic. Lesions appear as pink, smooth-surfaced, sessile, nontender papules that measure 2 to 6 mm in diameter. The central depression or umbilication has a white, waxy, curd-like core. Histologically, molluscum contagiosum exhibits a lobular proliferation of surface epithelium (figure 1); an aggregation of enlarged keratinocytes that are engorged with viral inclusions (molluscum bodies) can be seen in the center of the lesion (figure 2). Molluscum bodies have a homogenous, ground-glass, eosinophilic appearance.

Although the clinical appearance is characteristic, molluscum contagiosum must be differentiated from verruca vulgaris (wart), herpes simplex, epidermal inclusion cysts, and tumors of the skin. Molluscum contagiosum is a self-limiting disease, although many patients ask for treatment. Curettage and cryosurgery are the most common means of treatment. There is also a variety of topical treatments that are employed, some with greater success than others.

### Suggested reading

Hanson D, Diven DG. Molluscum contagiosum. *Dermatol Online J* 2003;9:2.

Whitaker SB, Wiegand SE, Budnick SD. Intraoral molluscum contagiosum. *Oral Surg Oral Med Oral Pathol* 1991;72:334-6.