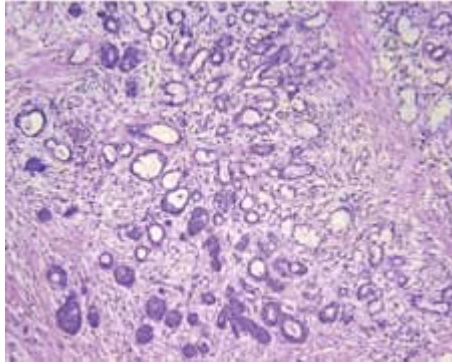


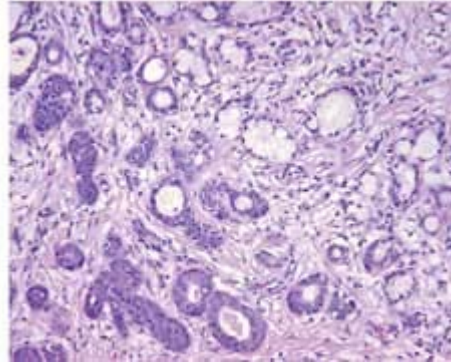
## Necrotizing sialometaplasia

Carla R. Penner, DDS

Lester D.R. Thompson, MD

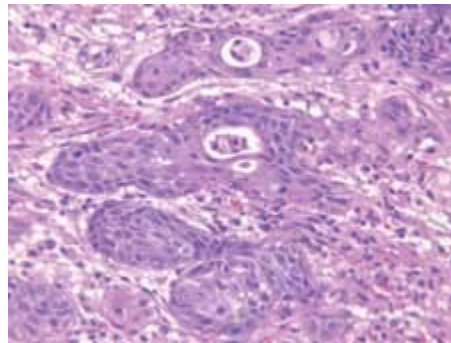


*Figure 1. A low-power view demonstrates the maintenance of the lobular structure of the minor salivary gland.*



*Figure 2. An intermediate-power view shows the uninvolved mucous glands (right side), which have been overtaken by the squamous metaplasia (left side) following the ischemic event.*

Necrotizing sialometaplasia is a benign, self-limited, reactive inflammatory process that involves salivary glands. It occurs in middle-aged patients; men are affected slightly more often than women. Patients may experience an antecedent event (e.g., surgery, radiation, or trauma) up to 3 weeks before necrotizing sialometaplasia appears clinically, but many are asymptomatic. A submucosal nodular swelling will give way to an ulcerative, crater-like lesion that usually measures less than 3 cm in its greatest dimension.



*Figure 3. A high-power view illustrates the smooth contour of the lobular unit, although there is mild to moderate nuclear pleomorphism, including prominent nucleoli, apoptotic cells, and mitotic figures. When viewed on high power alone, these changes can be misdiagnosed as representing squamous cell carcinoma.*

Necrotizing sialometaplasia most commonly arises in the minor salivary glands of the hard palate; other mucosal sites are affected less frequently. The histologic marker of necrotizing sialometaplasia is preservation of the smooth contour and lobular architecture of the salivary glands following coagulative necrosis and subsequent ductal and acinar squamous metaplasia

(figure 1). The metaplastic squamous epithelium has a bland overall histologic appearance (figure 2). However, as is the case with any reparative or regenerative epithelium, enlarged nuclei, prominent nucleoli, apoptosis, and mitotic figures can be seen (figure 3). Inflammatory cells, including neutrophils and lymphocytes, are often prominent in the surrounding tissues. In an attempt at re-epithelialization, necrotizing sialometaplasia may induce pseudoepitheliomatous hyperplasia, and this reaction may be so striking that distinguishing it from squamous cell carcinoma and mucoepidermoid carcinoma may be difficult. The difficulty is compounded when the biopsy specimen is small and features a predominance of fibrosis and inflammatory elements. The lobular architecture, the overall smooth edges of the epithelial islands, the uninvolved salivary glands, and the limited degree of cytologic atypia can help differentiate these diseases. Often the self-limiting nature of necrotizing sialometaplasia helps define the true nature of the disease.

No specific therapy is necessary, although it is important to define an etiologic agent, if possible, to prevent recurrence.

### **Suggested reading**

Brannon RB, Fowler CB, Hartman KS. Necrotizing sialometaplasia. A clinicopathologic study of sixty-nine cases and review of the literature. *Oral Surg Oral Med Oral Pathol* 1991;72:317-25.

Ellis GL, Auclair PL. Tumor-like conditions. In: Ellis GL, Auclair PL, eds. *Atlas of Tumor Pathology: Tumors of the Salivary Glands*. Fascicle 17. Washington D.C.: Armed Forces Institute of Pathology, 1995:413-19.