

Relapsing polychondritis

Lester D.R. Thompson, MD

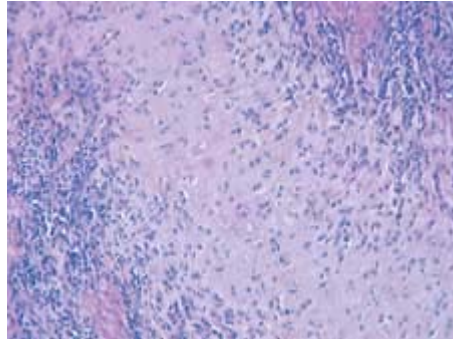


Figure 1. Intermediate power shows cartilage destroyed by inflammatory cells (small, blue-stained cells) at the right and left of the image. There is an overall loss of blue color in the cartilage and a disorganized architecture.

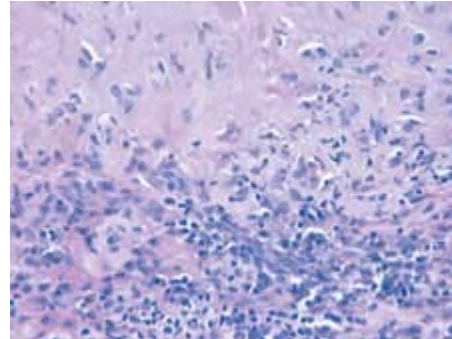


Figure 2. High power shows plasma cells (eccentrically located nuclei) and lymphocytes destroying the cartilage plate. There is cartilage dissolution and a decrease in the amount of the lacunar spaces.

Regardless of age, patients with relapsing polychondritis (systemic chondromalacia or polychondropathy) have at least one of eight progressively degenerative changes: (1) recurrent bilateral auricular chondritis, (2) inflammatory polyarthritis, (3) nasal chondritis, (4) ocular inflammation, (5) tracheal chondritis, (6) laryngeal chondritis, (7) cochlear damage, and (8) vestibular damage. Relapsing polychondritis is associated with other immunologically mediated diseases, such as systemic lupus erythematosus, rheumatoid arthritis, and Sjögren's syndrome.

Although gross findings are nonspecific, relapsing polychondritis is characterized by an overall thickening of the cartilage of the ear, nose, epiglottis, and cricoid and tracheal rings. The cartilage loses its basophilic quality (blue) and becomes more eosinophilic (red) as the disorder progresses. Fragmentation of the cartilage results in necrosis and lysis of the cartilaginous plates. The outer perichondrium (lining of cartilage) is permeated by a spectrum of inflammatory cells, including neutrophils, eosinophils, lymphocytes, and plasma cells (figures 1 and 2); these changes are frequently associated with edema or gelatinous cystic degeneration. As the disease progresses, the degenerated fibrillar cartilage imperceptibly blends with the surrounding inflammatory cells, leading to the formation of granulation-type tissue and fibrosis.

In making a diagnosis, it is necessary to exclude other diseases, including sarcoidosis, infection (e.g., tuberculosis, syphilis, and various fungal, bacterial, and viral infections), lymphoma, and Wegener's granulomatosis. Obtaining cultures or performing histochemical staining can help rule out infectious organisms, while clinical tests for cartilage matrix proteins or antibodies to type II collagen (found uniquely in cartilage) can help define relapsing polychondritis. Patients should be treated with either a corticosteroid or an immunosuppressive agent, depending on the severity of the disease.

Suggested reading

McAdam LP, O'Hanlan MA, Bluestone R, Pearson CM. Relapsing polychondritis: Prospective study of 23 patients and a review of the literature. *Medicine (Baltimore)* 1976;55:193-215.
McCaffrey TV, McDonald TJ, McCaffrey LA. Head and neck manifestations of relapsing polychondritis: Review of 29 cases. *Otolaryngology* 1978;86:473-8.