

## Malignant Transformation of a Dysembryoplastic Neuroepithelial Tumor After Radiation and Chemotherapy

Elisabeth J. Rushing, MD, Lester D. Thompson, MD, and Hernando Mena, MD

We describe a case of anaplastic astrocytoma in a 14-year-old boy arising at the site of a dysembryoplastic neuroepithelial tumor (DNT) 3 years after combined radiation and chemotherapy. The subtotally excised superficial right temporoparietal tumor was originally diagnosed as mixed oligoastrocytoma in 1974; the patient was treated with radiation therapy postoperatively. One year later he underwent a craniotomy to remove cyst fluid and no change was reported in the size of the residual tumor. Postoperatively, he received a 6-week course of chemotherapy (lovustine, CCNU). He remained clinically and radiographically stable until 3 years later, when seizure activity returned and imaging studies were consistent with tumor recurrence. He was lost to follow-up until 1986, when records showed that he had died. Review of the initial biopsy showed cortical fragments containing abundant calcifications and multinodular structures typical of the complex form of DNT, in addition to specific glioneuronal elements. The Ki-67 labeling index ranged from 0.1% to 3% focally. The specimen from the third surgery showed an anaplastic astrocytoma (Ki-67 up to 12%) and morphologic features characteristic of radiation effect. This is the first documented case of malignant transformation of DNT following radiation and adjuvant chemotherapy. The implications of malignant transformation in subtotally excised complex DNTs and the intriguing issue of the contribution of radiation/chemotherapy are discussed.

*Ann Diagn Pathol* 7: 240-244, 2003. © 2003 Elsevier Inc. All rights reserved.

**Index Words:** Brain tumor; child; radiation therapy; anaplastic astrocytoma; dysembryoplastic neuroepithelial tumor

**I**N 1988 Daumas-Duport et al<sup>1</sup> reported on a series of 39 patients, 1 to 19 years of age, with intractable partial-complex seizures associated with unique neuroepithelial tumors. The authors designated these tumors as dysembryoplastic neuroepithelial tumors (DNT) and provided evidence that they represent a distinct clinicopathologic entity. Morphologically, DNTs were found to share many common features including a cortical location, multinodular architecture, and heterogeneous neoplastic cellular elements consisting of astro-

cytes, neurons, and oligodendroglia.<sup>1-6</sup> Contiguous foci of cortical dysplasia were often present.<sup>1-3,7,8</sup> Subsequent reports by the original authors and other investigators have emphasized the histologic heterogeneity with revision of the World Health Organization Classification of Tumors of the Nervous System to include both "simple" and "complex" morphologic variants.<sup>7,9-14</sup> Long-term follow-up of all the original cases, including those that received radiation therapy, following total or incomplete resection, disclosed tumor-free survival of 1 to 18 years.<sup>1,3,4</sup> In this report we describe the first case of malignant transformation of DNT following radiation and chemotherapy.

### Case Report

On February 12th, 1974, at 14 years of age, this male patient was hospitalized following a 3-month history of worsening frontoparietal headaches, nausea, and vomiting. On examination, there was bilateral papilledema. Electroencephalogram showed

---

*From the Departments of Neuropathology and Ophthalmic Pathology and Otolaryngic and Endocrine Pathology, Armed Forces Institute of Pathology, Washington, DC.*

*Address reprint requests to Elisabeth J. Rushing, Colonel, Medical Corps, United States Army, Department of Neuropathology and Ophthalmic Pathology, Armed Forces Institute of Pathology, Washington, DC 20306-6000.*

© 2003 Elsevier Inc. All rights reserved.

1092-9134/03/0704-0006\$30.00/0

doi:10.1016/S1092-9134(03)00070-4

a right frontoparietal delta focus. Radiographic studies including brain scan and arteriogram, which confirmed a large superficial lesion in the right posterior parietal area with neovascularization and a posterior temporal component. The patient underwent a right temporal craniotomy, and an extensive cortical-based tumor in the mid-posterior temporoparietal lobe was subtotally resected. The pathologic diagnosis was mixed low-grade oligoastrocytoma. From February 27th to April 5th, 1975, the patient was referred for cobalt radiation therapy, which consisted of a course of 3,000 rads whole brain, followed by an additional 2,500 rads to the primary tumor site. He was apparently free of neurologic symptoms until February 1976, about 1 year after the initial surgery, when he experienced a generalized seizure. Examination of the surgical site revealed a mass pulsating through a 1 inch section of bone flap. A brain scan and arteriogram were abnormal and a second craniotomy was performed. At surgery, a large amount of fluid was drained from the site and the residual tumor, thought to be unchanged, was noted. Postoperatively, the patient received a 6-week course of oral CCNU chemotherapy. In March 1977, 3 years after the initial surgery, the patient experienced a recurrence of headaches and vomiting. Computerized tomography with intravenous contrast material revealed a mass with a small area of enhancement at the site of the two previous surgeries. A third craniotomy was performed and the tumor was grossly excised and interpreted as an anaplastic astrocytoma. Follow-up magnetic resonance imaging in September 1977 showed no evidence of residual tumor. The patient was lost to follow-up until 1986, when review of social security records showed that he had died. Additional information could not be obtained.

Microscopic sections from the initial resection were stained with hematoxylin-eosin and reviewed and compared with slides from the third surgery by the authors. Additional immunohistochemical stains including neurofilament proteins, Ki-67, synaptophysin, and glial fibrillary acidic protein were prepared from the accompanying paraffin blocks. Examination of tissue samples obtained at the time of the first surgical procedure showed multiple discrete cortical tumor nodules (Fig 1A) composed of a mixture of glial fibrillary acidic protein-positive astrocytic and glial fibrillary acidic protein-negative oligodendroglial-like components with foci of mi-

crocalcifications (Fig 1B). In addition, the neoplastic nodules contained several glioneuronal elements consisting of isolated neurons suspended in a pale eosinophilic matrix. Synaptophysin immunolabeling highlighted the neuronal cytoplasm and processes within the glioneuronal component. Mitotic activity, vascular changes, or necrosis were not identified. The Ki-67 labeling index varied from 0.1% to 3.0% focally. These morphologic features represented the complex form of DNT. Review of sections from the recurrent tumor obtained at the time of the third surgery revealed an infiltrating glial neoplasm composed of moderately pleomorphic cells, mostly of astrocytic lineage, accompanied by vascular endothelial hyperplasia and conspicuous mitotic activity (Fig 1C). There were foci of tumor with morphologic features similar to the original biopsy, including collections of oligodendrogloma-like areas. Necrosis was not identified. Histopathologic features of radiation injury included areas of vascular hyalinization and hyperchromatic bizarre-appearing nuclei. Sections stained for Ki-67 revealed a labeling index of up to 12% in the more cellular areas. These histologic findings were diagnostic of a high-grade glioma, namely an anaplastic astrocytoma.

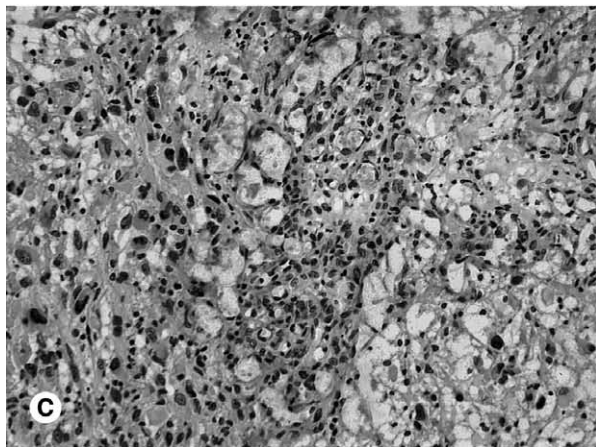
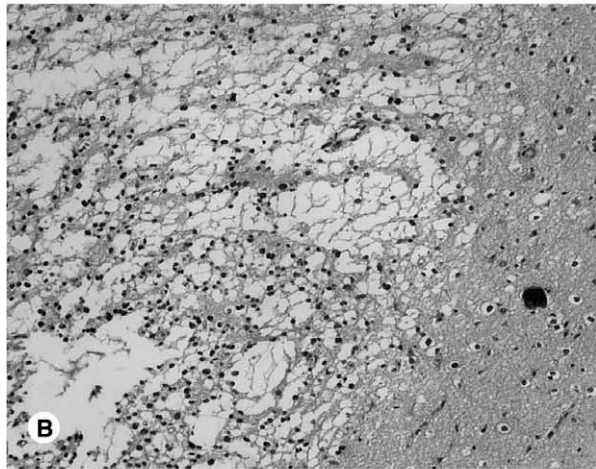
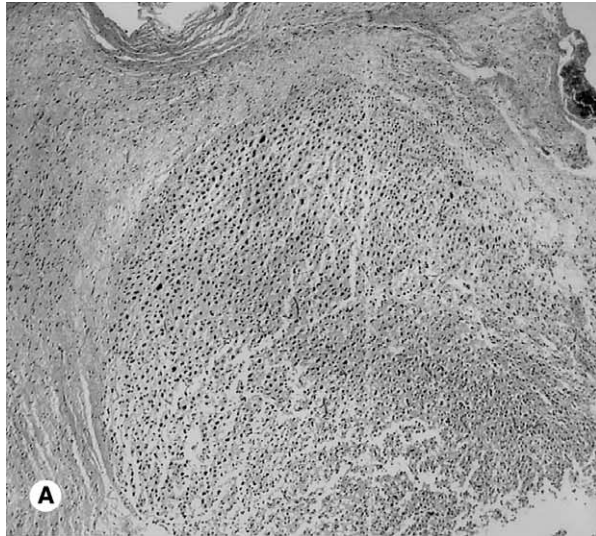
### Discussion

The induction of central nervous system tumors within the irradiated field and the malignant transformation of a previously low-grade tumor are among the recognized adverse effects of radiotherapy.<sup>7,8,15-17</sup> According to Huang et al,<sup>15</sup> the criteria that define radiation-induced tumors are as follows: the tumor has a long quiescent or "latency period," the location is in a previously irradiated field, and there is a verified histologic difference from the primary condition. In the present case, the anaplastic astrocytoma identified at the third surgery fulfilled the latter two criteria. Moreover, histopathologic features of radiation injury were identified in the tissue samples. The latency period in the present case was only 3 years; however, the combined mutagenic effects of radiation and chemotherapy may have accelerated the malignant transformation.<sup>18</sup> The precise mechanisms that correlate irradiation with oncogenesis are not completely understood. A number of studies clearly implicate radiation and chemotherapy-induced deletions of critical DNA sequences as an important

event in triggering radiation-induced carcinogenesis.<sup>8,15</sup>

An alternative explanation is that the malignant transformation within the residual neoplastic tissue occurred independent of radiation or chemotherapy. In the original series of 39 cases by Daumas-Duport,<sup>1</sup> 17 patients underwent subtotal resection with no clinical or radiologic evidence of recurrence on long-term follow-up. In the 13 patients in the original study who had undergone postoperative radiotherapy compared with the 26 subjects who had not received radiotherapy, there was no difference in survival or recurrence.<sup>1</sup> In another series of patients with DNT who underwent temporal lobectomy for seizure control, there was adequate seizure control and no recurrences despite subtotal resection.<sup>19</sup> Conversely, the recent case report by Hammond et al<sup>20</sup> presents compelling evidence of the malignant potential of an incompletely resected DNT. In that case, the pathologic specimen obtained during subtotal removal of the tumor was originally diagnosed as a microcystic astrocytoma and the patient received no additional therapy. The patient remained well for 11 years, at which time progressive seizure activity recurred and imaging studies showed a recurrent enhancing partially cystic lesion. A glioblastoma multiforme, which contained a single focus reminiscent of DNT, was resected. Review of the original biopsy confirmed the diagnosis of DNT of the complex form.<sup>20</sup> In another recent report, Nakatsuka<sup>21</sup> published a case of an unclassified tumor closely resembling DNT with rapid growth in a 3-year-old girl who presented with a single generalized seizure. The tumor was restricted to the cortex, but lacked the specific glioneuronal element. These two cases and the present case challenge the widespread belief that all DNTs are slow-growing neoplasms and that incompletely excised DNTs have a uniformly favorable prognosis.

Although our case antedated the debut of DNT



←  
**Figure 1.** (A) Photomicrograph from the original biopsy showing a representative cortical nodule typical of the complex form of DNT. (Hematoxylin-eosin stain, magnification  $\times 120$ .) (B) Original biopsy with focus of calcification adjacent to the sharply demarcated neoplasm with microcystic features (Hematoxylin-eosin stain, magnification  $\times 230$ .) (C) Histologic features of the third biopsy specimen, dominated by microvascular proliferation and astrocytic pleomorphism (Hematoxylin-eosin stain, magnification  $\times 330$ .)

in the scientific literature, which underscores the potential pitfalls that persist in diagnosing this uncommon entity. In particular, stereotactic biopsies need to be interpreted with caution because of sampling limitations. The original diagnosis in our patient was oligoastrocytoma. On the basis of this diagnosis and the presence of residual neoplasm, the patient received adjuvant therapy. Indeed, the differential diagnosis of DNT includes oligodendroglioma, mixed oligoastrocytoma, ganglioglioma, and hamartoma. There are reliable morphologic clues to help distinguish these similar entities. It is notable that although oligodendrogliomas may include nodular foci, they lack the neuronal component of DNT.<sup>4,20,22-25</sup> Hamartomas are characterized by the presence of disordered neuronal elements, without evidence of astrocytic or oligodendroglial components.<sup>9,21,26</sup> Gangliogliomas are not intracortical and do not exhibit multinodular architecture. Gangliogliomas have an abundant reticulin-rich connective tissue stroma and often contain perivascular inflammatory infiltrates, which are absent in DNT.<sup>3,9,21,22,27</sup> Of note, mixed or transitional neoplasms containing both discrete DNT and ganglioglioma components have been cited in the literature.<sup>11,13,28</sup> The heterogeneous histopathologic features of DNTs and the recognition of the increasing number of morphologic variants of this entity continue to present a diagnostic challenge.<sup>4,20,29</sup> The distinction of DNT from more aggressive neoplasms can be facilitated if viewed as a clinicopathologic entity.<sup>4,8,30,31</sup> Dumas-Duport<sup>1</sup> emphasizes that whatever the histologic appearance of a glial tumor, the diagnosis of DNT must be considered when the following criteria are associated: (1) partial seizures, with or without secondary generalization, beginning before the age of 20 years; (2) no neurologic deficit or stable congenital deficit; (3) cortical topography of the lesion as better demonstrated by magnetic resonance imaging; and (4) no mass effect on imaging. An increasing number of reports have described DNTs in extracortical sites.<sup>17,26,29,32-35</sup> For example, a recent report by Baisden et al<sup>29</sup> identifies 10 DNT-like neoplasms in the septum pellucidum. Another series of 11 cases of glioneuronal tumors with histologic features resembling DNT were found in the fourth ventricle.<sup>26</sup> These reports provide strong evidence that DNTs may occur in other sites than the cerebral cortex.

In summary, we have presented the case of ma-

lignant transformation of a DNT following radiation and chemotherapy. Although it is not currently feasible to confirm the mutagenic role of these agents in an individual case, in the present case, there is convincing circumstantial evidence linking the two events. This case illustrates that DNTs may demonstrate a somewhat unpredictable biological behavior that warrants close monitoring.

## References

1. Dumas-Duport C, Scheithauer BW, Chodkiewicz JP, et al: Dysembryoplastic neuroepithelial tumor: A surgically curable tumor of young patients with intractable partial seizures. Report of thirty-nine cases. *Neurosurgery* 1988;23:545-556
2. Abe M, Tabuchi K, Tsuji T, et al: Dysembryoplastic neuroepithelial tumor: report of three cases. *Surg Neurol* 1995;43:240-245
3. Dumas-Duport C: Dysembryoplastic neuroepithelial tumors. *Brain Pathol* 1993;3:283-295
4. Dumas-Duport C, Varlet P, Bacha S, et al: Dysembryoplastic neuroepithelial tumors: Nonspecific histological forms – A study of 40 cases. *J Neurooncol* 1999;41:267-280
5. Dirks PB, Jay V, Becker LE, et al: Development of anaplastic changes in low-grade astrocytomas of childhood. *Neurosurgery* 1994;34:68-78
6. Kleihues P, Cavenee W. *Pathology and Genetics: Tumors of the Nervous System*. Lyonpp 103-106, IARC Press, 2000
7. Nishio S, Morioka T, Inamura T, et al: Radiation-induced brain tumours: Potential late complications of radiation therapy for brain tumours. *Acta Neurochir (Wien)* 1998;140:763-770
8. Weichselbaum RR, Beckett MA, Diamond AA: An important step in radiation carcinogenesis may be inactivation of cellular genes. *Int J Radiat Oncol Biol Phys* 1989;16:277-282
9. Hanovar M, Janota I, Polkey CE: Histological heterogeneity of dysembryoplastic neuroepithelial tumor: Identification and differential diagnosis in a series of 74 cases. *Histopathology* 1999;34:342-356
10. Hirose T, Scheithauer BW, Lopes MB, et al: Dysembryoplastic neuroepithelial tumor (DNT): An immunohistochemical and ultrastructural study. *J Neuropathol Exp Neuropathol* 1994;53:184-195
11. Prayson RA: Composite ganglioglioma and dysembryoplastic neuroepithelial tumor. *Arch Pathol Lab Med* 1999;123:247-250
12. Raghavan R, White CL III, Rogers B, et al: Alpha-synuclein expression in central nervous system tumors showing neuronal or mixed neuronal/glial differentiation. *J Neuropathol Exp Neurol* 2000;59:490-504
13. Shimbo Y, Takahashi H, Hayano M, et al: Temporal lobe lesion demonstrating features of dysembryoplastic neuroepithelial tumor and ganglioglioma: A transitional form? *Clin Neuropathol* 1997;16:65-68
14. Taratuto AL, Pomata H, Sevlever G, et al: Dysembryoplastic neuroepithelial tumor: Morphological, immunocytochemical, and deoxyribonucleic acid analyses in a pediatric series. *Neurosurgery* 1995;36:474-481
15. Huang CI, Chiou WH, Ho DM: Oligodendroglioma occurring after radiation therapy for pituitary adenoma. *J Neurol Neurosurg Psych* 1987;50:1619-1624

16. Kaido T, Hoshida T, Uranishi R, et al: Radiosurgery-induced brain tumor. Case report. *J Neurosurg* 2001;95:710-713
17. Schwarz AM, Ghatak NR: Malignant transformation of benign cerebellar astrocytoma. *Cancer* 1990;65:333-336
18. Murnane JP: Role of induced genetic instability in the mutagenic effects of chemicals and radiation. *Mutat Res* 1996;367:11-23
19. Kirkpatrick PJ, Hanovar M, Janota I, et al: Control of temporal lobe epilepsy following en bloc resection of low-grade tumors. *J Neurosurg* 1993;78:19-25
20. Hammond RR, Duggal N, Wolfe JM, et al: Malignant transformation of a dysembryoplastic neuroepithelial tumor: Case report. *J Neurosurg* 2000;92:722-725
21. Nakatsuka M, Mizuno S, Kimura T, et al: A case of an unclassified tumor closely resembling dysembryoplastic neuroepithelial tumor with rapid growth. *Brain Tumor Pathol* 2000;7:41-45
22. Leung SY, Gwi E, Ng HK, et al: Dysembryoplastic neuroepithelial tumor: A tumor with small neuronal cells resembling oligodendroglioma. *Am J Surg Pathol* 1994;18:604-614
23. Whittle IR, Dow GR, Lammie GA, et al: Dysembryoplastic neuroepithelial tumour with discrete bilateral multifocality: further evidence for a germinal origin. *Br J Neurosurg* 1999;13:508-511
24. Wolf HK, Wellmer J, Muller MB, et al: Glioneuronal malformative lesions and dysembryoplastic neuroepithelial tumors in patients with chronic pharmacoresistant epilepsies. *J Neuropathol Exp Neurol* 1995;54:245-254
25. Yasha TC, Mohanty A, Radhesh S, et al: Dysembryoplastic neuroepithelial tumor (DNT) associated with Arnold-Chiari malformation. *Clin Neuropathol* 1998;17:305-310
26. Komori T, Scheithauer BW, Hirose T: A rosette-forming glioneuronal tumor of the fourth ventricle: Infratentorial form of dysembryoplastic neuroepithelial tumor? *Am J Surg Pathol* 2002;5:582-591
27. Prayson RA, Estes ML: Dysembryoplastic neuroepithelial tumor. *Am J Clin Pathol* 1992;97:398-401
28. Hirose T, Scheithauer BW: Mixed dysembryoplastic neuroepithelial tumor and ganglioglioma. *Acta Neuropathol (Berl)* 1998;95:649-654
29. Iwanaga K, Takahashi H, Kameyama S, et al: Dysembryoplastic neuroepithelial tumor: Report of a case without typical glioneuronal elements. *Acta Neuropathol (Berl)* 1995;89:284-289
30. Baisden BL, Brat DJ, Melhem ER, et al: Dysembryoplastic neuroepithelial tumor-like neoplasm of the septum pellucidum: A lesion often misdiagnosed as glioma: Report of 10 cases. *Am J Surg Pathol* 2001;25:494-499
31. Lee DY, Chung CK, Hwang YS, et al: Dysembryoplastic neuroepithelial tumor: Radiological findings (including PET, SPECT, and MRS) and surgical strategy. *J Neurooncol* 2000;47:167-174
32. Cervera-Pierot P, Varlet P, Chodkiewicz JP, et al: Dysembryoplastic neuroepithelial tumors located in the caudate nucleus area: Report of four cases. *Neurosurgery* 1997;40:1065-1069
33. Fujimoto K, Ohnishi H, Tsujimoto M, et al: Dysembryoplastic neuroepithelial tumor of the cerebellum and brainstem: Case report. *J Neurosurg* 2000;93:487-490
34. Tatke M, Sharma A, Malhotra V: Dysembryoplastic neuroepithelial tumour. *Childs Nerv Syst* 1998;14:293-296
35. Wolf HK, Buslei R, Blumcke I, et al: Neural antigens in oligodendrogliomas and dysembryoplastic neuroepithelial tumors. *Acta Neuropathol (Berl)* 1997;94:436-443
36. Raymond AA, Halpin SF, Alsanjari N, et al: Dysembryoplastic neuroepithelial tumor: Features in 16 patients. *Brain* 1994;117:461-475
37. Wong K, Gyure KA, Prayson RA, et al: Dysembryoplastic neuroepithelial tumor: In situ hybridization of proteolipid protein (PLP) messenger ribonucleic acid (mRNA). *J Neuropathol Exp Neurol* 1999;58:542 (abstr)