

## Hodgkin-Like Transformation of a Marginal Zone B-Cell Lymphoma of the Larynx

Eric K. Fung, MD, Thomas S. Neuhauser, MD, and Lester D.R. Thompson, MD

Primary larynx lymphomas, specifically of the mucosa-associated lymphoid tissue, are a rare but documented phenomenon. Transformation of any type of lymphoma that has the presence of Reed-Sternberg cells is unusual in lymph nodes and exceptional in extranodal sites. Herein, we report the first case (to the best of our knowledge in a review of the English literature [MEDLINE 1966-2001]) in which both of these unusual findings are present; that is, an extranodal marginal zone B-cell lymphoma of laryngeal mucosa-associated lymphoid tissue with Hodgkin-like transformation. The patient is a 78-year-old man who presented with intermittent shortness of breath, progressive dysphagia, and intermittent hoarseness. On examination, a large mass of the left supraglottic larynx was identified with a "ball-valve" effect into the laryngeal inlet with inspiration. Examination of the neck showed no palpable masses. Histologic examination of the incisional biopsy showed replacement of the submucosa by sheets of atypical monocytoid B cells (CD20+, CD79a+, lambda+, CD3-) characterized by nuclear atypia, mitotic activity, plasmacytoid differentiation, and restricted for lambda light chains. Dutcher bodies were easily identified. Interspersed throughout the neoplastic lymphoid population were numerous Reed-Sternberg cells and variants immunoreactive for CD30 and CD15 and nonreactive for CD45RB. The patient was treated with 44 cGy to the neck and larynx and was alive and free of disease at last contact, 2.6 years after the original presentation.

*Ann Diagn Pathol* 6: 61-66, 2002. Copyright © 2002 by W.B. Saunders Company

**Index Words:** Larynx, mucosa-associated lymphoid tissue, lymphoma, transformation, Hodgkin lymphoma

**M**ARGINAL zone B-cell lymphoma of mucosa-associated lymphoid tissue (MALT), or MALToma, in the larynx is a rare but well-documented occurrence. Numerous case reports exist in the literature documenting hematopoietic neoplasia arising from the larynx with no other known anatomic site of involvement.<sup>1-18</sup>

---

*From the Department of Otolaryngology and Communication Sciences, Upstate Medical University, Syracuse, NY; the Department of Endocrine and Otorhinolaryngic-Head & Neck Pathology, Armed Forces Institute of Pathology, Washington, DC; and the Department of Pathology, Wilford Hall Medical Center, Lackland Air Force Base, San Antonio, TX.*

*The opinions or assertions contained herein are the private views of the authors and are not to be construed as official or as reflecting the views of the Department of Defense.*

*Address reprint requests to Lester D.R. Thompson, MD, Department of Endocrine and Otorhinolaryngic-Head and Neck Pathology, 6825 16th St, NW, Armed Forces Institute of Pathology, Bldg 54, Room G066-11, Washington, DC 20306-6000.*

*Copyright © 2002 by W.B. Saunders Company*

*1092-9134/02/0601-007\$35.00/0*

*doi:10.1053/adpa.2002.30611*

Also well-documented but rare is the transformation of a non-Hodgkin lymphoma with the presence of cells that are morphologically similar to the Reed-Sternberg cells of Hodgkin lymphoma.<sup>19-29</sup> This transformation of low-grade lymphoma to a higher grade lymphoma is often described as a Richter's transformation, a term that originally described transformation of B-cell chronic lymphocytic leukemia (CLL)/small lymphocytic lymphoma to more aggressive large B-cell lymphoma as an end-stage event.<sup>30</sup>

To our knowledge, however, there has been no case report that documents a Hodgkin-like Richter's transformation of a laryngeal lymphoma. In the following reported case, we describe an isolated laryngeal lymphoma with Reed-Sternberg (RS) cells and variants (RS-H) identified within the background of a nodular marginal zone lymphoma with monocytoid B cells.

### Materials and Methods

Materials within the files of the Armed Forces Institute of Pathology (Washington, DC) were supplemented by a

Table 1. Immunohistochemical Reagents

Antibody	Primary Antibody	Company	Dilution	Antigen Unmasking
CD3	rp	Dako Corp; Carpinteria, CA	1:500	Protease treatment
CD5	mm	Vector/Novocastra Labs; Burlingame, CA	1:100	Microwave pretreatment
CD10	mm	Vector/Novocastra	1:100	Microwave pretreatment
CD15 (LeuM1)	mm	Becton Dickinson; Mountain View, CA	1:40	None
CD20 (L26)	mm	Dako	1:200	None
CD23	mm	The Binding Site; San Diego, CA	1:200	Pepsin treatment
CD30 (Ki-1)	mm	Dako	1:40	Protease treatment
CD43 (MT1)	mm	Biotest; Denville, NJ	1:50	None
CD45RA (MT2)	mm	Biotest	1:20	None
CD45RB (LCA)	mm	Dako	1:200	None
CD45RO (UCHL-1)	mm	Dako	1:200	None
CD79a	mm	Dako	1:200	Microwave pretreatment
bcl-1 (cyclin D1)	mm	Immunotech; Marseilles, France	1:3,000	Microwave pretreatment
bcl-2	mm	Dako	1:100	Microwave pretreatment
Kappa	rp	Dako	1:25,000	Protease treatment
Lambda	rp	Dako	1:50,000	Protease treatment
EBV-LMP	rp	Dako	1:80	Protease treatment

Abbreviations: mm; mouse monoclonal; rp; rabbit polyclonal; EBV-LMP; Epstein-Barr virus latent membrane protein.

review of the patient's symptoms and physical findings at presentation, past medical and surgical history, and follow-up information about treatment and the patient's current status. The Musshoff's modification of the Ann Arbor staging system was used. Stage IE is described as a laryngeal or mucosal lymphoma with or without extension into the perilaryngeal soft tissue and stage IIE includes involvement of lymph nodes on the same side of the diaphragm.<sup>31</sup> Hematoxylin-eosin-stained slides were examined in conjunction with immunohistochemical studies (Table 1). Immunophenotypic analysis was performed by the standardized avidin-biotin method of Hsu et al<sup>32</sup> using 4- $\mu$ m thick, formalin-fixed, paraffin-embedded sections. Positive and negative tissue controls were used for each antibody. This clinical investigation was conducted in accordance and compliance with all statutes, directives, and guidelines of the Code of Federal Regulations, Title 45, Part 46, and the Department of Defense Directive 3216.2 relating to human subjects in research.

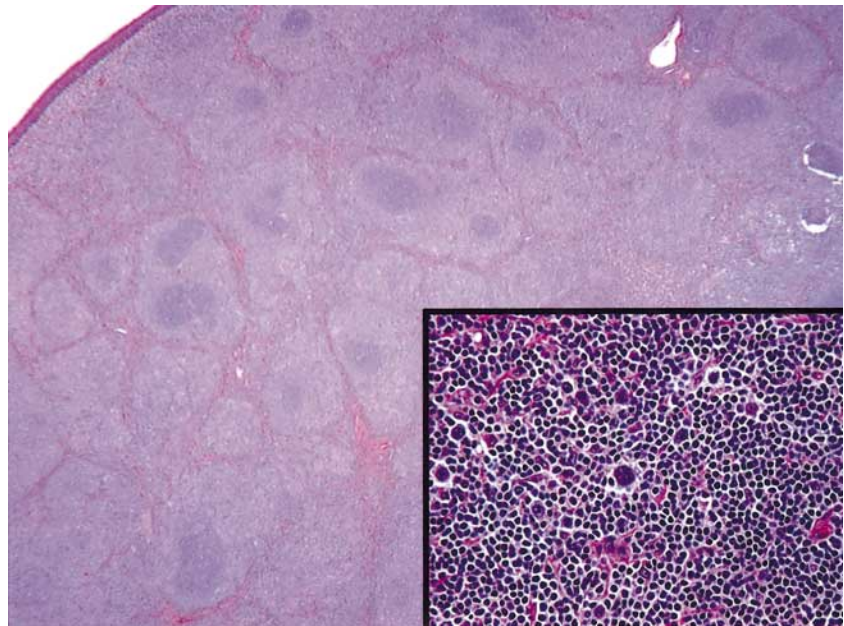
### Case Report

A 78-year-old white man presented with intermittent shortness of breath, progressive dysphagia, and intermittent hoarseness, present for the past 3 months. There was no other pertinent past medical or surgical history. Fever, chills, and weight loss were not elicited from the patient. Physical examination showed a large mass of the left supraglottic larynx that had a "ball-valve" effect with inspiration. The recurrent laryngeal nerve appeared to be intact. There were no palpable masses on neck exam-

ination or by radiographic analysis. A wide excisional biopsy was obtained that showed a smooth, encapsulated, yellow-tan, fish flesh mass measuring 3.0  $\times$  2.2  $\times$  1.0 cm. Surface ulceration was not appreciated.

Histologic examination disclosed an intact and uninvolved squamous epithelium (Fig 1). The normal stromal constituents of the larynx were completely replaced by a sheet-like to nodular arrangement of atypical lymphoid cells (Fig 1). Small lymphoid cells with variable proportions of centrocyte-like cells, plasma cells, lymphoplasmacytoid lymphocytes, monocytoid B cells, and interspersed large transformed cells with Reed-Sternberg-like morphology were noted (Fig 1). The monocytoid B cells varied from small to intermediate-sized cells containing round, oval, or slightly irregular nuclei with dark chromatin and moderate to abundant amounts of clear or pale eosinophilic cytoplasm. Cytologic atypia in monocytoid B cells was recognized by nuclear enlargement and irregular shape with open chromatin and conspicuous nucleoli. Cytoplasmic immunoglobulin accumulations and Dutcher bodies were noted. The large atypical cells demonstrated centroblastic-like, immunoblastic, and Reed-Sternberg-like features with the Reed-Sternberg cells and Reed-Sternberg variant cells predominating (Fig 2).

The monocytoid population was strongly immunoreactive with CD45RB, CD20, and CD79a, and showed restriction for lambda light chains (Fig 2). Focal bcl-2 coexpression also was noted. The large atypical Reed-Sternberg cells and variants were immunoreactive for CD30 and CD15, but negative for CD45RB. A few of

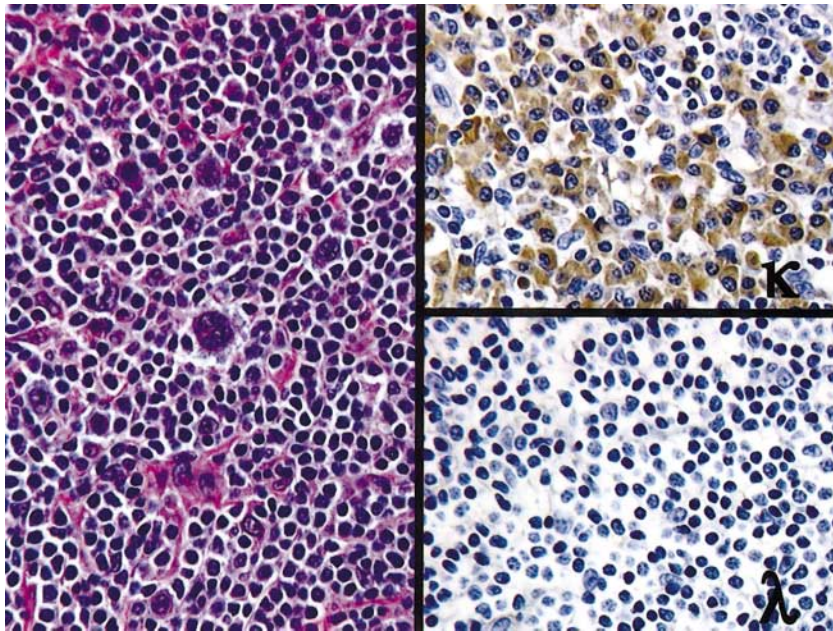


**Figure 1.** A low power image shows the complete effacement of the stroma (epithelium is visible in the upper left corner). The inset shows a number of Reed-Sternberg cells and variants.

these cells also reacted with CD20. The latent membrane protein of Epstein Barr virus was negative. T cells were highlighted by CD3 and CD45RO. There was nonreactivity with CD5, CD10, CD23, CD43, CD45RA, and bcl-1.

The patient was classified as a stage IE without documented lymph node disease or any systemic manifestations. He was treated with 44 cGy in 22 fractions to

include the larynx and neck. He remained free of disease at last contact 2.6 years following presentation. However, of clinical interest, this patient developed two other, unrelated malignancies. He presented with dysphagia and some difficulty swallowing 11 months after the diagnosis of the laryngeal lymphoma. The incisional biopsy was diagnosed as a moderately differentiated squamous



**Figure 2.** A high power image shows plasmacytoid cells with monocytoid B-cells with Reed-Sternberg cells and variants. The kappa immunohistochemical reaction demonstrates restriction.

cell carcinoma of the midesophagus, managed with 33 cGy to the thorax and lower neck. An additional 11 months later he developed weight loss, changes in bowel habits, and hemepositive stool. After a work-up that revealed a poorly differentiated adenocarcinoma, he was treated by a partial colectomy (sigmoid colon and upper rectum) for a stage II, T3NOMO tumor. No additional therapy was planned at the time of last contact.

### Discussion

Extranodal marginal zone B-cell lymphomas of mucosa associated lymphoid tissue (MALTomas) are fairly common lymphoid neoplasms, accounting for approximately 25% to 40% of all lymphomas.<sup>33</sup> While many MALTomas arise in native MALT, such as Peyer's patches in the gastrointestinal tract, the most common site of MALToma is the stomach, which is devoid of native MALT. Chronic gastritis, usually caused by *Helicobacter pylori*, is thought to induce the formation of lymphoid tissue. This induced lymphoid tissue is thought to be a necessary precursor to MALToma. A similar phenomenon is seen in thyroid and salivary gland MALTomas that are preceded by Hashimoto's thyroiditis and benign lymphoepithelial lesion or myoepithelial sialadenitis, respectively.<sup>34,35</sup> The larynx, however, is an anatomic site devoid of native lymphoid tissue. To our knowledge, there is no well-characterized chronic inflammatory process thought to be a precursor to laryngeal MALToma.

Several variants of laryngeal lymphoma have been reported<sup>16</sup> and have been seen in conjunction with cytomegalovirus infection of the larynx,<sup>12</sup> and with squamous cell carcinoma of the larynx.<sup>4</sup> Unique to our case of laryngeal MALToma is the presence of Reed-Sternberg cells and variants in a background of extranodal marginal zone B-cell lymphoma. Reed-Sternberg-like cells are known to occur in a wide variety of lymphoma subtypes and in reactive lymphoid proliferations, but these cells are true Reed-Sternberg cells by immunohistochemistry. The clinical significance of these cells is not entirely clear. Although required for the diagnosis of Hodgkin lymphoma, the presence of Reed-Sternberg cells is not diagnostic because these cells can be found in other reactive and neoplastic entities. As such, Hodgkin lymphoma is defined as the presence of Reed-Sternberg cells in an *appropriate background*.<sup>36</sup> Given this definition, one element in the differential diagnosis of this tumor was nodular lymphocyte predominance type of Hodgkin lymphoma (NLPHD).

Two findings are inconsistent with this diagnosis. First is the relative abundance of RS and RS variant cells found in our case that should be rare in a typical case of NLPHD.<sup>36</sup> Second is the immunophenotype of the RS and RS variant cells: the RS cell in NLPHD is usually CD15 negative and immunoreactive for CD45RB (leukocyte common antigen),<sup>36</sup> whereas the RS and RS variant cells in this case were immunoreactive for CD15 and negative for CD45RB.

Another diagnostic consideration for the tumor in this case was a *composite tumor*. Composite lymphomas are defined as two histologically distinct variants of lymphoma occurring in the same organ or mass.<sup>30</sup> The different lymphomas in a composite lymphoid malignancy should be distinctly divided. One such composite MALToma that showed classic histologic features of marginal zone B-cell lymphoma with adjacent Hodgkin lymphoma of the mixed cellularity subtype has been reported in the small intestine.<sup>37,38</sup> In this clinical case, there is an absence of the typical Hodgkin disease background of heterogeneous inflammatory cells surrounding these Reed Sternberg cells and there are not two distinct cell populations, separable from one another. Therefore, the aggregate of findings suggests a Hodgkin-like transformation of the marginal zone B-cell lymphoma rather than a composite tumor.

The role of Epstein-Barr virus in the development of Reed-Sternberg cells has been debated. A case series by Momose et al<sup>26</sup> found 12 of 13 cases of CLL with RS-H cells to be reactive for Epstein-Barr virus (EBV) RNA by in situ hybridization. Two cases of CLL reported by Rubin et al<sup>20</sup> with RS-H cells were also found to be EBV reactive by RNA in situ hybridization. Four of five patients who underwent fludarabine treatment for low-grade B-cell lymphomas and underwent a Hodgkin-like transformation also showed EBV reactivity by RNA in situ hybridization.<sup>38</sup> These results have led to some speculation that immunosuppression caused by the underlying non-Hodgkin's lymphoma or resultant chemotherapy may predispose these patients to EBV infection and subsequent Hodgkin-like transformation.<sup>28</sup> Kingma et al<sup>28</sup> retrospectively studied cases of non-Hodgkin's lymphoma associated with Hodgkin lymphoma and found that only six of 35 patients in this group showed EBV reactivity on in situ RNA assays. Our case was found to be EBV negative by latent membrane protein assay.

The prognosis for this patient is difficult to predict given the singularity of the histopathology present in the lymphoma. Both radiotherapy<sup>1-3,8,9,11,12,14,15,17,18</sup> and chemotherapy<sup>7,10,13,15</sup> have been reported as single-modality approaches to the treatment of laryngeal lymphoma. Also described are combination chemotherapy and radiotherapy<sup>5</sup> as well as radiation failure necessitating total laryngectomy.<sup>2</sup> In general, the prognosis for localized lymphoma of the larynx has been good, with few recurrences after local radical radiotherapy.

In conclusion, we present a case of a low-grade marginal zone B-cell lymphoma with Hodgkin-like transformation localized to the larynx. The Reed-Sternberg-like cells are EBV negative by latent membrane protein analysis. To our knowledge, this represents the only reported case of a laryngeal MALToma with evidence of Hodgkin-like transformation.

#### Acknowledgement

The authors thank Dr Martin P. McCann for contribution of the case.

#### References

1. Ansell SM, Habermann TM, Hoyer JD, et al: Primary laryngeal lymphoma. *Laryngoscope* 1997;107:1502-1506
2. Kato S, Sakura M, Takooda S, et al: Primary non-Hodgkin's lymphoma of the larynx. *J Laryngol Otol* 1997;111:571-574
3. Ohta N, Suzuki H, Fukase S, et al: Primary non-Hodgkin's lymphoma of the larynx (Stage IE) diagnosed by gene rearrangement. *J Laryngol Otol* 2001;115:596-599
4. Hisashi K, Komune S, Inoue H, et al: Coexistence of MALT type lymphoma and squamous cell carcinoma of the larynx. *J Laryngol Otol* 1994;108:995-997
5. Diebold J, Audouin J, Viry B, et al: Primary lymphoplasmacytic lymphoma of the larynx: A rare localization of MALT-type lymphoma. *Ann Otol Rhinol Laryngol* 1990;99:577-580
6. Horny HP, Ferlito A, Carbone A: Laryngeal lymphoma derived from mucosa-associated lymphoid tissue. *Ann Otol Rhinol Laryngol* 1996;105:577-583
7. Kawaida M, Fukuda H, Shiotani A, et al: Isolated non-Hodgkin's malignant lymphoma of the larynx presenting as a large pedunculated tumor. *ORL J Otorhinolaryngol Relat Spec* 1996;58:171-174
8. Ghosh KC, Chatterjee DN, Mukherjee D, et al: Primary non-Hodgkin's lymphoma of larynx (a case report). *J Postgrad Med* 1986;32:103-104
9. Cheng CJ, Chen PR, Liu MC, et al: Primary malignant lymphoma of mucosa-associated lymphoid tissue of larynx. *Otolaryngol Head Neck Surg* 1999;121:661-662
10. Cavalot AL, Preti G, Vione N, et al: Isolated primary non-Hodgkin's malignant lymphoma of the larynx. *J Laryngol Otol* 2001;115:324-326
11. de Bree R, Mahieu HF, Ossenkuppele CJ, et al: Malignant lymphoma of mucosa-associated lymphoid tissue in the larynx. *Eur Arch Otorhinolaryngol* 1998;255:368-370
12. Siegel RJ, Browning D, Schwartz DA, et al: Cytomegaloviral laryngitis and probable malignant lymphoma of the larynx in a patient with acquired immunodeficiency syndrome. *Arch Pathol Lab Med* 1992;116:539-541
13. Blatsios V, Bouros D, Emmanouel A, et al: Primary non-Hodgkin's lymphoma of the larynx treated only by chemotherapy. *Chest* 1990;98:1547
14. Morgan K, MacLennan KA, Narula A, et al: Non-Hodgkin's lymphoma of the larynx (stage IE). *Cancer* 1989;64:1123-1127
15. Hessian H, Houck J, Harvey H: Airway obstruction due to lymphoma of the larynx and trachea. *Laryngoscope* 1988;98:176-180
16. Horny HP, Kaiserling E: Involvement of the larynx by hematopoietic neoplasms. An investigation of autopsy cases and review of the literature. *Pathol Res Pract* 1995;191:130-138
17. Stepnick D, Sawyer R: Isolated subglottic lymphomas. *Otolaryngol Head Neck Surg* 1989;101:578-580
18. Swerdlow JB, Meri SA, Davey FR, et al: Non-Hodgkin's lymphoma limited to the larynx. *Cancer* 1984;53:2546-2549
19. O'Sullivan MJ, Kaleem Z, Bolger MJ, et al: Composite polymphocytoid and Hodgkin transformation of chronic lymphocytic leukemia. *Arch Pathol Lab Med* 2000;124:907-909
20. Rubin D, Hudnall SD, Aisenberg A, et al: Richter's transformation of chronic lymphocytic leukemia with Hodgkin's-like cells is associated with Epstein-Barr virus infection. *Mod Pathol* 1994;7:91-98
21. Ohno T, Smir BN, Weisenburger DD, et al: Origin of the Hodgkin/Reed-Sternberg cells in chronic lymphocytic leukemia with "Hodgkin's transformation". *Blood* 1998;91:1757-1761
22. Pescarmona E, Pignoloni P, Mauro FR, et al: Hodgkin/Reed-Sternberg cells and Hodgkin's disease in patients with B-cell chronic lymphocytic leukaemia: An immunohistological, molecular and clinical study of four cases suggesting a heterogeneous pathogenetic background. *Virchows Arch* 2000;437:129-132
23. Williams J, Schned A, Cotelingam JD, et al: Chronic lymphocytic leukemia with coexistent Hodgkin's disease. Implications for the origin of the Reed-Sternberg cell. *Am J Surg Pathol* 1991;15:33-42
24. Weisenberg E, Anastasi J, Adeyanju M, et al: Hodgkin's disease associated with chronic lymphocytic leukemia. Eight additional cases, including two of the nodular lymphocyte predominant type. *Am J Clin Pathol* 1995;103:479-484
25. Tsang WY, Chan JK, Sing C: The nature of Reed-Sternberg-like cells in chronic lymphocytic leukemia. *Am J Clin Pathol* 1993;99:317-323
26. Momose H, Jaffe ES, Shin SS, et al: Chronic lymphocytic leukemia/small lymphocytic lymphoma with Reed-Sternberg-like cells and possible transformation to Hodgkin's disease. Mediation by Epstein-Barr virus. *Am J Surg Pathol* 1992;16:859-867
27. Shin SS, Ben-Ezra J, Burke JS, et al: Reed-Sternberg-like cells in low-grade lymphomas are transformed neoplastic cells of B-cell lineage. *Am J Clin Pathol* 1993;99:658-662
28. Kingma DW, Medeiros LJ, Barletta J, et al: Epstein-Barr virus is infrequently identified in non-Hodgkin's lymphomas associated with Hodgkin's disease. *Am J Surg Pathol* 1994;18:48-61
29. Cha I, Herndier BG, Glassberg AB, et al: A case of composite Hodgkin's disease and chronic lymphocytic leukemia

in bone marrow. Lack of Epstein-Barr virus. *Arch Pathol Lab Med* 1996;120:386-389

30. Jaffe ES, Zarate-Osorno A, Medeiros LJ: The interrelationship of Hodgkin's disease and non-Hodgkin's lymphomas—Lessons learned from composite and sequential malignancies. *Semin Diagn Pathol* 1992;9:297-303

31. Carbone PP, Kaplan HS, Musshoff K, et al: Report of the Committee on Hodgkin's Disease Staging Classification. *Cancer Res* 1971;31:1860-1861

32. Hsu SM, Raine L, Fanger H: Use of avidin-biotin-peroxidase complex (ABC) in immunoperoxidase techniques: A comparison between ABC and unlabeled antibody (PAP) procedures. *J Histochem Cytochem* 1981;29:577-580

33. Isaacson PG: Mucosa-associated lymphoid tissue lymphoma. *Semin Hematol* 1999;36:139-147

34. Derringer GA, Thompson LD, Frommelt RA, et al: Malignant

lymphoma of the thyroid gland: A clinicopathologic study of 108 cases. *Am J Surg Pathol* 2000;24:623-639

35. Abbondanzo SL: Extranodal marginal-zone B-cell lymphoma of the salivary gland. *Ann Diagn Pathol* 2001;5:246-254

36. Knowles DM: Hodgkin's Disease: Histopathology and differential diagnosis, in Knowles DM, (ed): *Neoplastic Hematopathology*. Baltimore, MD, Williams & Wilkins, 1992, pp 497-534

37. Aguilera NS, Howard LN, Brissette MD, et al: Hodgkin's disease and an extranodal marginal zone B-cell lymphoma in the small intestine: An unusual composite lymphoma. *Mod Pathol* 1996;9:1020-1026

38. Shields DJ, Byrd JC, Abbondanzo SL, et al: Detection of Epstein-Barr virus in transformations of low-grade B-cell lymphomas after fludarabine treatment. *Mod Pathol* 1997;10:1151-1159