
ORIGINAL ARTICLES

Nodular Fasciitis of the External Ear Region: A Clinicopathologic Study of 50 Cases

Lester D.R. Thompson, MD, Julie C. Fanburg-Smith, MD, and Bruce M. Wenig, MD

Nodular fasciitis (NF), uncommon in the auricular area, is a benign reactive myofibroblastic proliferation that may be mistaken for a neoplastic proliferation. Fifty cases of NF of the auricular region were identified in the files of the Otorhinolaryngic-Head and Neck Tumor Registry of the Armed Forces Institute of Pathology. The patients included 22 females and 28 males, aged 1 to 76 years (mean, 27.4 years). The patients usually presented clinically with a mass lesion (n = 49). Five patients recalled antecedent trauma. The lesions were dermal (n = 28) or subcutaneous (n = 11) in those cases where histologic determination was possible, measuring 1.9 cm on average. The majority of the lesions were circumscribed (n = 38), composed of spindle-shaped to stellate myofibroblasts arranged in a storiform growth pattern, juxtaposed to hypocellular myxoid tissue-culture-like areas with extravasation of erythrocytes. Dense, keloid-like collagen and occasional giant cells were seen (n = 18). Mitotic figures (without atypical forms) were readily identifiable. By immunohistochemical staining, myofibroblasts were reactive with vimentin, actins, and CD68. All patients had surgical excision. Four patients (9.3%) developed local recurrence and were alive and disease free at last follow-up. All patients with follow-up (n = 43) were alive or had died of unrelated causes, without evidence of disease an average 13.4 years after diagnosis. Nodular fasciitis of the auricular area occurs most often in young patients. Because NF is more often dermally situated than extremity NF, it may present with superficial ulceration and/or bleeding. Local recurrence is more frequent because of the difficulty in obtaining complete surgical excision around the ear.

Ann Diagn Pathol 5: 191-198, 2001. This is a US government work. There are no restrictions on its use.

Index Words: Nodular fasciitis, ear, auricular region, differential diagnosis, immunohistochemistry, myofibroblasts

From the Departments of Endocrine and Otorhinolaryngic-Head & Neck Pathology and Soft Tissue Pathology, Armed Forces Institute of Pathology, Washington, DC.

Presented at the 87th Annual Meeting of the United States and Canadian Academy of Pathology, Boston, MA, February 28 – March 7, 1998.

The opinions or assertions contained herein are the private views of the authors and are not to be construed as official or as reflecting the views of the Department of Defense.

Address reprints requests to Lester D.R. Thompson, MD, Department of Endocrine & Otorhinolaryngic-Head & Neck Pathology, Building 54, Room G066-11, Armed Forces Institute of Pathology, 6825 16th St, NW, Washington, DC 20306-6000.

This is a US government work. There are no restrictions on its use.

1092-9134/01/0504-0001\$0.00/0

doi:10.1053/adpa.2001.26969

Table 1. Auricular Nodular Fasciitis Immunohistochemical Panel

Antibody	Primary Antibody	Company	Dilution	Cellular Conditioning
Keratin cocktail (AE1/AE3 and CK1)	mm	Boehringer Mannheim Biochemicals, Indianapolis, IN, and Dako, Carpinteria, CA	1:50 1:200	Protease treatment
Smooth muscle actin	mm	Sigma Immuno Chemicals, St Louis, MO	1:8,000	None
S-100 protein	rp	Dako	1:800	None
Glial fibrillary acidic protein	rp	Dako	1:2,000	Protease treatment
XIIIA	rp	Calbiochem, San Diego, CA	1:1,000	Protease treatment
Vimentin	mm	Biogenex, San Ramon, CA	1:800	Microwave pretreatment
Muscle specific actin	mm	Enzo, Farmingdale, NY	1:80	None
Desmin	mm	Dako	1:100	Protease treatment
HMB-45	mm	Dako	1:100	None
CD34	mm	Dako	1:40	Microwave pretreatment
KP-1	mm	Dako	1:200	Protease treatment

Abbreviations: mm, mouse monoclonal; rp, rabbit polyplonal.

NODULAR fasciitis (NF) is generally regarded as a benign, reactive, tumor-like proliferation of myofibroblasts that typically occurs in the extremities. The head and neck region is a common location for NF, particularly in children, but NF of the auricular region is rare. Therefore, we undertook this study in order to more completely define the clinical, histologic, and immunophenotypic features of NF of the ear region and to compare these findings with NF occurring in more usual locations.

Materials and Methods

Fifty patients with a diagnosis of auricular NF were identified in the files of the Otorhinolaryngic-Head & Neck Pathology Registry at the Armed Forces Institute of Pathology from the years 1970 to 1990. These 50 cases were identified in a review of 2,930 (1.9%) benign and malignant auricular neoplasms and soft tissue reactive conditions seen in consultation during the same reference period. Forty-four cases were obtained from civilian sources, five from military hospitals, and one from a Veterans Administration medical center.

Materials within the Institute's files were supplemented by a review of the patient demographics (gender, age), symptoms at presentation (including duration), and past medical history (specifically, a history of trauma). In addition, we reviewed surgical pathology and operative reports and obtained follow-up information from oncology data services by written questionnaires or direct communication with the treating physician or the patient. Follow-up data included the exact location, size, treatment modalities, and current patient and disease

status and was available for 43 patients. This clinical investigation was conducted in accordance and compliance with all statutes, directives, and guidelines of the Code of Federal Regulations Title 45, Part 46, and the Department of Defense Directive 3216.2 relating to human subjects in research.

Hematoxylin-eosin-stained slides from all patients were reviewed for morphologic assessment to meet the established diagnostic criteria for NF.¹ Further, all cases had to primarily involve the auricular region, specifically defined for this study as ear, not further specified, immediately preauricular, postauricular, infraauricular, auricular (pinna), or the external auditory canal (lateral to the tympanic membrane). Immunophenotypic analysis was performed in 32 cases (64%) with suitable material by using the standardized avidin-biotin method of Hsu et al² using 4 μ m-thick, formalin fixed, paraffin embedded sections. Table 1 documents the pertinent, commercially available immunohistochemical antibody panel used. The analysis was performed on a single representative block in each case. When required for cellular conditioning, proteolytic antigen retrieval was performed by pre-digestion for 3 minutes with 0.05% protease VIII (Sigma Chemical Co, St Louis, MO) in 0.1-mol/L concentration of phosphate buffer, pH of 7.8, at 37°C. Antigen enhancement (recovery) was performed as required by using formalin fixed, paraffin embedded tissue that was treated with a buffered citric acid solution and heated for 20 minutes in a calibrated microwave oven. Afterwards, the sections were allowed to cool at room temperature in a citric acid buffer solution for 45 minutes before continuing the procedure. Standard positive controls were used throughout, with serum used as the negative control. While we anticipated positivity for vimentin, for the

Table 2. Auricular Nodular Fasciitis: Mean Size and Duration of Symptoms by Location

Anatomic Site	Number	Size (cm)	Duration of Symptoms (mos)
Ear, not otherwise specified	5	2.0	2.2
External auditory canal	6	1.3	1.6
Pinna	2	2.3	4.0
Preauricular	18	1.8	4.4
Posterior auricular	19	2.1	7.7
Total	50	1.9	5.0

actins and KP-1 we chose S-100 protein and HMB-45 to rule out desmoplastic melanomas, glial fibrillary acidic protein to rule out neural and adnexal tumors, cytokeratin to rule out epithelial lesions, CD34 to rule out dermatofibrosarcoma protuberans and Kaposi's sarcoma (because of the similar extravasated red blood cells), and factor XIIIa for the reactivity of passenger cells in many fibrohistiocytic lesions in the differential diagnosis.

Categorical variables were analyzed using chi-square tests to compare observed and expected frequency distributions, except when small sample size (less than five) indicated the use of Fisher's exact test. Comparison of means between groups were made with unpaired t-tests or one-way analysis of variance, depending on whether there were two or more groups. Multiple comparisons were analyzed using the Tukey method. Confidence intervals of 95% were generated for all positive findings. The alpha level was set at $P < .05$. All statistical analysis was performed with the computer software package, Statistical Package for the Social Sciences 8.0 for PC (SPSS; Chicago, IL).

Results

Patient Demographics and Clinical Presentation

The patients included 22 females and 28 males, whose ages ranged from 1 to 76 years of age, with a mean of 27.4 years of age. The mean age at presentation for females, 31.5 years, was slightly older than for males, 24.1 years, but this difference was not statistically significant. Forty nine (98%) patients presented clinically with a mass lesion; one patient presented with a change in hearing only (conductive hearing loss). Additionally, five patients also had associated pain and five had associated bleeding. Of the five patients with a mass and bleeding, two also had surface ulceration and another had an associated malodorous discharge. Five patients had a history of antecedent trauma.

Three of these patients identified the use of a cotton tipped applicator in the ear canal before the development of an external auditory canal lesion, whereas an additional patient was struck by a belt buckle in the preauricular region. The remaining patient described an injury of uncertain nature to the preauricular region. The duration of symptoms ranged from a few days to 36 months, with a mean of 5 months. While, on average, there was a shorter duration of symptoms for patients with external auditory canal lesions (1.6 months) when compared with the average for all locations combined (5.0 months) (Table 2), this difference was not statistically significant.

Contributing Diagnoses

The most frequent misdiagnoses for the ear NF cases were (in order of frequency) dermatofibrosarcoma protuberans, fibrosarcoma, leiomyosarcoma, malignant fibrous histiocytoma, proliferative fasciitis, inflammatory pseudotumor, fibromatosis, fibrous histiocytoma, and benign peripheral nerve sheath tumors. Clinical impressions included necrotizing fasciitis, perichondritis, and squamous cell carcinoma with ulceration.

Treatment and Follow-up

All patients were treated surgically, with or without complete removal of the lesion. Follow-up data was available in 43 patients. Of these 43 patients, 41 were alive and two had died of unrelated causes without evidence of disease, with a mean follow-up of 13.4 years (range, 0.4 to 29.0 years; median, 11.4 years). Four patients developed local recurrence (two of whom had previous trauma), from 1 month to 12 years after therapy. Three of these probably represented residual disease, as the recurrences occurred at 2, 4, and 7 months after excision, respectively. Of these three cases, two were from the posterior auricular region, and one from the external auditory canal. The patients were treated by re-excision of the lesion, and were without evidence of disease at last follow-up. The remaining patient developed NF at the same site (posterior auricular region) 12 years after the initial presentation, and was treated by surgical excision. This patient is also presently disease free. We are unsure whether this second lesion in the patient represents recurrent disease or a new primary lesion. The five patients with antecedent trauma tended to have an

Table 3. Auricular Nodular Fasciitis: Histologic Features

Anatomic Site	Total	Soft Tissue Location	Growth Pattern
Ear, not otherwise specified	5	D = 5	C = 3 I = 1 U = 1
External auditory canal	6	D = 4 SQ = 1 U = 1	C = 4 U = 2
Pinna	2	D = 2	C = 2
Preauricular	18	D = 8 F = 1 SQ = 7 U = 2	C = 14 I = 3 U = 1
Posterior auricular	19	D = 9 F = 3 SQ = 3 U = 4	C = 15 I = 3 U = 1
Total	50	D = 28 F = 4 SQ = 11 U = 7	C = 38 I = 7 U = 5

Abbreviations: D, dermal; SQ, subcutaneous; F, fascial; U, unknown; C, circumscribed; I, infiltrative.

increased chance of recurrence (40%; $P = .045$). However, the specific location (dermal, subcutaneous, or fascial), the anatomic site, bleeding and/or ulceration, young patient age, neural entrapment,

skeletal muscle entrapment/atrophy, or size of the lesion did not increase the chance of recurrence or residual disease.

Pathology

Macroscopic features. The majority of lesions were received as multiple, irregular fragments, described as soft or firm, glistening, fleshy, homogeneous to variegated masses, that were gray, white, tan-pale, brown, red, or yellow, occasionally with an ulcerated surface or with old blood. The excised specimens measured 0.4 to 8 cm in greatest dimension (Table 2) with an mean of 1.9 cm. Whereas the smallest lesions tended to occur in the external auditory canal (mean, 1.3 cm), this finding was not statistically significant.

Microscopic features. The location of the lesion was dermal in 28 cases (Table 3) (Fig 1), subcutaneous in 11, and fascial in four. Because of fragmentation, an accurate determination of exact location was impossible in the remaining seven cases. All dermal lesions were considered to be superficial, while subcutaneous or fascial lesions were considered deep. Most of the external auditory canal cases (four of six) and all of the ear, not otherwise specified, and pinna cases ($n = 7$) were dermal. Of the five patients with bleeding, four had superficial (dermal) lesions: three were external auditory canal and one was posterior auricular. Additionally, the two patients with ulceration both had superficial (dermal) external auditory canal

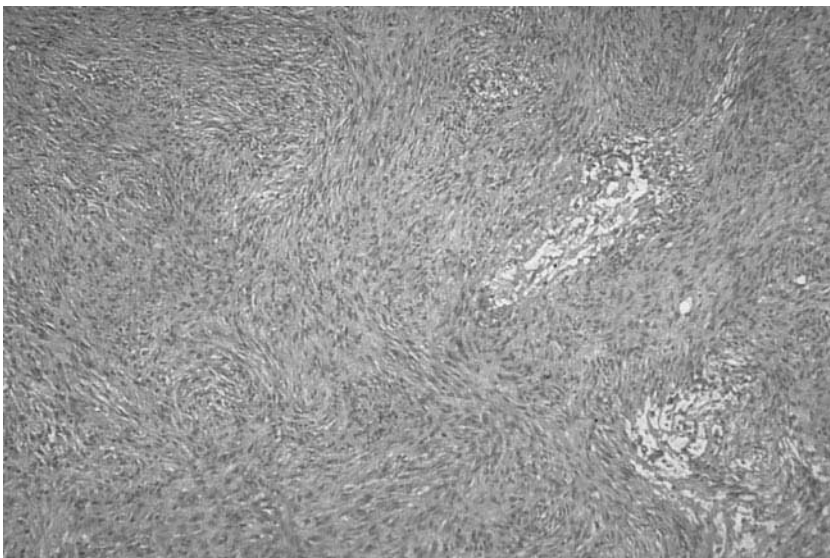


Figure 1. Dermal nodular fasciitis composed of a spindle cell proliferation with areas of myxoid degeneration.

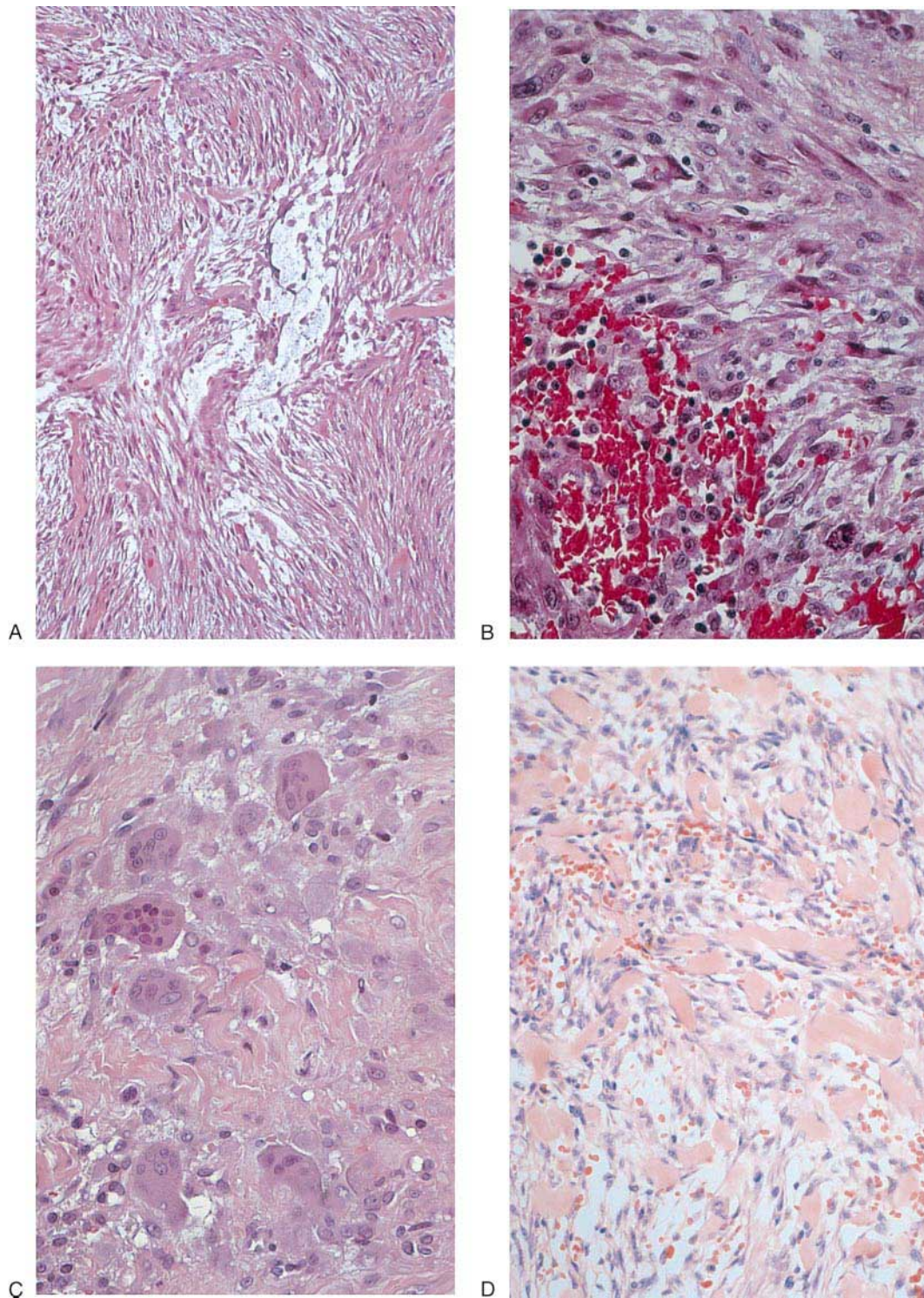


Figure 2. (A) Nodular fasciitis is characterized by a tissue-culture-like myofibroblastic proliferation with loose, myxoid areas. (B) Extravasated erythrocytes. (C) Osteoclast-type giant cells. (D) Nodular fasciitis showing the presence of dense, keloid-like collagen deposition coupled with extravasated erythrocytes.

lesions. One of the 15 patients with a deep lesion had bleeding (also in the external auditory canal). Among 45 cases in which the pattern of growth could be determined, 38 were well circumscribed, while seven were irregular and infiltrative into the surrounding soft tissues. In rare cases involving skeletal muscle, the skeletal muscle fibers showed compression atrophy ($n = 6$), with a number of cases demonstrating neural entrapment ($n = 7$). The lesions were composed of a loosely cellular proliferation of tissue-culture-like myofibroblastic cells arranged in a loosely storiform growth pattern, juxtaposed to hypocellular myxoid areas (Fig 2A) with extravasated erythrocytes (Fig 2B) and lymphocytes. The lesional cells were spindle shaped to stellate in appearance with oval nuclei, abundant basophilic cytoplasm, and variably sized nucleoli. Occasional multinucleated giant cells were identified (Fig 2C) in 20 cases. Macrophages were focally abundant in two cases. Dense, keloid-like collagen was present in variable amount in 48 cases (Fig 2D). Mitotic figures were easily identified in 46 cases (a mean of more than 10 per 10 high power fields with 40 x objective), but without atypical forms.

Immunohistochemical findings. While immunohistochemical studies were not necessary for the diagnosis of NF, the lesional cells were reactive for vimentin, smooth muscle actin, muscle specific actin, and KP-1. All cases were negative for desmin, S-100 protein, cytokeratins, CD34, HMB-45, glial fibrillary acidic protein, and factor XIIIa. The immunostains, when positive, showed strong cytoplasmic positivity. There were no differences in the immunoreactive staining pattern based on anatomic location or temporal occurrence of the lesions.

Discussion

Nodular fasciitis was first described by Konwaler et al³ in 1955. Although NF of the head and neck is common,⁴⁻²¹ particularly in children, NF of the auricular region is uncommon. We could only find rare case reports of auricular NF in a review of the English literature,^{7,13,21} one of which was considered an example of cranial fasciitis.⁷ The only bona fide case of NF of the ear that we could identify was reported by Katahashi et al,¹³ and involved the auricle of a 53-year-old man. At our institution, NF

of the ear comprised only 1.5% of all 3,930 NF cases arising in all anatomic sites from 1970 to 1990, and represented 1.9% of all auricular lesions (reactive, benign, or malignant lesions). Therefore, NF in this location is exceedingly rare, without any patient series reported in the English literature (Medline 1966-2001). Similar to NF elsewhere,¹ auricular NF is frequent in young patients, with a mean age at presentation of 27 years, and is small in size (mean, 1.9 cm). However, there are a few differences between auricular NF when compared with extremity lesions. Nodular Fasciitis of the ear tends to be more superficially situated than extremity NF, with 65% of our cases dermally based, whereas a dermal location is rare in extremity NF.^{22,23} This observation is supported by the dearth of soft tissue in the auricular region, and therefore, a greater number of cases (14%; 4 of 28) develop ulceration and bleeding, especially when compared with extremity lesions. In fact, patients with bleeding and ulceration were much more likely to have dermal-based NF as compared with patients in which NF was situated in nondermal locations ($P = .013$). While recurrence in NF is a well-known phenomenon,¹⁶ NF has a higher propensity for local recurrence in the auricular area in our series (9.3%) than in other regions, where reported recurrence rates range from 1% to 2% of cases.¹ Two factors may account for an increased recurrence: (1) increased auricular trauma ($P = .045$), and (2) the difficulty in obtaining complete surgical excision because of the anatomic confines of the auricular region, especially the external auditory canal. As noted in our series, the recurrences were often described within a few months of the initial presentation, and no doubt represent residual disease rather than recurrence, especially since all patients were without disease at last follow-up. This distinction cannot be reliably made by histomorphologic examination. We are unable to make a comparison of the influence of trauma on the development of NF of the auricular region when compared with other anatomic sites of the head and neck, or in the extremities, as valid numbers are not readily available. Furthermore, no features studied, including location, anatomic site, neural entrapment, skeletal muscle atrophy, giant cells, keloid-like collagen, or hemorrhage, was independently correlated with patient recurrence or outcome.

We found a longer duration of symptoms in our patients than for extremity cases reported in the

literature.¹ While the presence of keloid-like collagen is described irrespective of the length of symptoms, the presence of keloid-like collagen in nearly all of our cases (96%) may be correlated to the longer duration of symptoms, although we could not prove this hypothesis based on the present study.

Nodular fasciitis in more usual locations is frequently incorrectly considered a neoplastic lesion because of its rapid growth, presence of a high cellularity, abundant mitotic figures, and capacity to be poorly circumscribed. Nodular fasciitis of the ear region is also frequently misdiagnosed. In our series, a diagnosis other than NF was rendered in 75% of the cases with 30% (9 of 30 cases) considered sarcomas by the contributing pathologists. As such, there was an overall malignant misdiagnosis rate of 23% in our cases, similar to the cases in the literature.¹⁶ The most frequent misdiagnoses were dermatofibrosarcoma protuberans, fibrosarcoma, leiomyosarcoma, and malignant fibrous histiocytoma. However, the lack of nuclear atypia, a lack of a herringbone fascicular growth pattern, and an absence of atypical mitotic figures should assist in separating NF from malignant tumor. Although myofibroblasts may occasionally be positive for desmin, we have not observed this finding in NF. Despite the fact that some smooth muscle tumors may be negative for desmin, one can generally use desmin, especially when it is strongly staining, in addition to the morphology and strength of the actins staining, to separate smooth muscle tumors from NF. Because NF occurs in younger patients, the misdiagnosis of malignancy has grave consequences because the management of sarcomas of the head and neck, in young people especially, tends to be aggressive. Therefore, accurate diagnosis of NF is essential to avert inappropriately aggressive management.

In addition to sarcomas, the histologic differential diagnosis for NF includes other reactive myofibroblastic proliferations, such as proliferative fasciitis^{24,25} and inflammatory pseudotumor,^{26,27} and benign lesions such as fibromatosis, fibrous histiocytoma, and benign peripheral nerve sheath tumors. The rather distinctive histologic appearance of NF, including alternating cellular tissue-culture-like myofibroblasts, keloid-like collagen, and paucicellular myxoid change with extravasation of erythrocytes and lymphocytes will help distinguish NF from these lesions.

Despite the presence of keloid-like collagen in some of our cases, NF lacks the purposeful direction of myofibroblasts, elongate vessels, and infiltrative growth pattern of fibromatosis. Nodular fasciitis is generally a cellular and circumscribed lesion. S-100 protein can be used to separate NF from benign nerve sheath tumors, as the latter is typically diffusely and strongly positive for S-100 protein. Perhaps more specific to the ear, clinical misdiagnosis might include necrotizing fasciitis, perichondritis²⁸ or squamous cell carcinoma with ulceration. However, these lesions have characteristic histomorphologic properties that allow for differentiation from NF. In conclusion, NF of the ear occurs infrequently, but should be considered in the differential diagnosis of an auricular mass with associated ulceration or bleeding. Awareness of the rather distinctive microscopic features of NF will help to distinguish it from other benign and malignant entities. Although surgically challenging given the anatomic constraints of this region, complete local excision is strongly advised as it would likely decrease the higher potential for recurrence of NF in the auricular area.

Acknowledgments

The authors wish to thank Lucher Duckett for his expert photography, R. Allen Frommelt for his statistical analysis, and Pamela A. Thompson for her conscientious research assistance.

References

1. Enzinger FM, Weiss SW: Benign fibrous tissue tumors, in Enzinger FM, Weiss SW (eds): *Soft Tissue Tumors* (ed 3). St Louis, MO, Mosby, 1995, pp 167-176
2. Hsu SM, Raine L, Fanger H: Use of avidin-biotin-peroxidase complex (ABC) in immunoperoxidase techniques: A comparison between ABC and unlabeled antibody (PAP) procedures. *J Histochem Cytochem* 1981;29:577-580
3. Konwaler BE, Keasbey L, Kaplan L: Subcutaneous pseudo-sarcomatous fibromatosis (fasciitis): Report of 8 cases. *Am J Clin Pathol* 1995;25:241-248
4. Abendroth CS, Fraunhoffer EE: Nodular fasciitis of the parotid gland. Report of a case with presentation in an unusual location and cytologic differential diagnosis. *Acta Cytol* 1995;39:530-534
5. Badia DM, Rossi L, Socri AR, et al: Oral nodular fasciitis. A case report. *Eur J Cancer B Oral Oncol* 1994;30B:221-222
6. Chen KT, Bauer V: Nodular fasciitis presenting as parotid tumor. *Am J Otolaryngol* 1987;8:179-181
7. Clapp CG, Dodson EE, Pickett BP, et al: Cranial fasciitis presenting as an external auditory canal mass. *Arch Otolaryngol Head Neck Surg* 1997;123:223-225
8. Dahl I, Jarlstedt J: Nodular fasciitis in the head and neck. A clinicopathological study of 18 cases. *Acta Otolaryngol* 1980;90:152-159

9. Davies HT, Bradley N, Bowerman JE: Oral nodular fasciitis. *Br J Oral Maxillofac Surg* 1989;27:147-151
10. Di Nardo LJ, Wetmore RF, Potsic WP: Nodular fasciitis of the head and neck in children. A deceptive lesion. *Arch Otolaryngol Head Neck Surg* 1991;117:1001-1002
11. Fischer JR, Abdul-Karim FW, Robinson RA: Intraparotid nodular fasciitis. *Arch Pathol Lab Med* 1989;113:1276-1278
12. Hermans R: Nodular fasciitis: A case at the level of the zygomatic arch]. *J Belge Radiol* 1990;73:493-495
13. Katahashi T, Shimada F, Omura K, et al: A case of nodular fasciitis arising in the auricle. *Auris Nasus Larynx* 1995;22:59-64
14. Lando M, Abemayor E, Mendoza V: Pathologic quiz case I. Nodular fasciitis of the parotid gland. *Arch Otolaryngol Head Neck Surg* 1991;117:336-338
15. Meffert JJ, Kennard CD, Davis TL, et al: Intradermal nodular fasciitis presenting as an eyelid mass. *Int J Dermatol* 1996;35:548-552
16. Montgomery EA, Meis JM: Nodular fasciitis. Its morphologic spectrum and immunohistochemical profile. *Am J Surg Pathol* 1991;15:942-948
17. Mostofi RS, Soltani K, Beste L, et al: Intraoral periosteal nodular fasciitis. *Int J Oral Maxillofac Surg* 1987;16:505-509
18. Robertson B, Roche WC, Shabb B: Nodular fasciitis: A case report. *J Oral Maxillofac Surg* 1986;44:236-239
19. Van Royen C, Wackens G, Goossens A: Nodular fasciitis in a temporomandibular joint. *Int J Oral Maxillofac Surg* 1993;22:168-170
20. Werning JT: Nodular fasciitis of the orofacial region. *Oral Surg Oral Med Oral Pathol* 1979;48:441-446
21. Milo AG, Vito KJ, Kinney SE, et al: Nodular fasciitis arising in the external auditory canal. *Otolaryngol Head Neck Surg* 1999;120:591-592
22. Price SK, Kahn LB, Saxe N: Dermal and intravascular fasciitis. Unusual variants of nodular fasciitis. *Am J Dermatopathol* 1993;15:539-543
23. Lai FM, Lam WY: Nodular fasciitis of the dermis. *J Cutan Pathol* 1993;20:66-69
24. Chung EB, Enzinger FM: Proliferative fasciitis. *Cancer* 1975;36:1450-1458
25. Samaratunga H, Searle J, O'Loughlin B: Nodular fasciitis and related pseudosarcomatous lesions of soft tissues. *Aust N Z J Surg* 1996;66:22-25
26. Nochomovitz LE, Orenstein JM: Inflammatory pseudotumor of the urinary bladder—Possible relationship to nodular fasciitis. Two case reports, cytologic observations, and ultrastructural observations. *Am J Surg Pathol* 1985;9:366-373
27. Wenig BM, Devaney K, Bisceglia M: Inflammatory myofibroblastic tumor of the larynx. A clinicopathologic study of eight cases simulating a malignant spindle cell neoplasm. *Cancer* 1995;76:2217-2229
28. Skorina J, Kaufman D: Necrotizing fasciitis originating from pinna perichondritis. *Otolaryngol Head Neck Surg* 1995;113:467-473